

Wei-Hsin Chien · Ching-Chung Liang

Iatrogenic bladder stone and associated vesicovaginal fistula after hysterectomy

Received: 24 August 2005 / Accepted: 23 December 2005 / Published online: 28 February 2006
© Springer-Verlag Berlin / Heidelberg 2006

Abstract A patient had irritative lower urinary tract symptoms for 2 years after hysterectomy. During cystoscopy, a bladder stone was seen and removed, but watery vaginal discharge emerged. The subsequent transvaginal ultrasound revealed a fistulous tract between the bladder and the vagina. The methylene blue test further confirmed the diagnosis of vesicovaginal fistula. We performed a delayed Latzko procedure to successfully repair the fistula.

Keywords Vesicovaginal fistula · Bladder stone · Suture material · Vaginal ultrasound

Introduction

A variety of bladder stones has been reported in women with previous hysterectomy or colposuspension [1, 2]. Though vesicovaginal fistula is not a rare complication of hysterectomy [3], primary vesical calculi are uncommon in women with vesicovaginal fistula and are associated with urinary contamination [4]. We report a rare case of iatrogenic bladder stone after hysterectomy and subsequent vesicovaginal fistula formation.

Case report

A 49-year-old, gravida 3, para 2 woman was referred to our urogynecology clinic because of frequency and urgency for the previous 2 years with unsuccessful anticholinergic drug treatment. She had had an abdominal hysterectomy because of a large uterine myoma 2 years previously, and intermittent small amounts of watery vaginal discharge

developed 2 months after the operation. Her lower urinary tract symptoms had also been noted since that time.

Urinalysis was normal, and a urodynamic study showed a small maximum cystometric capacity. Cystoscopy disclosed a canary-yellow stone embedded in the bladder mucosa above the trigone, and a small hole was seen after we removed the stone (Fig. 1a). We performed vaginal ultrasound to evaluate the lower urinary tract and found a fistulous tract between the bladder wall and the upper vagina (Fig. 1b). The methylene blue test confirmed a patent vesicovaginal fistula. We performed a delayed Latzko procedure to repair the fistula, and the result was satisfactory.

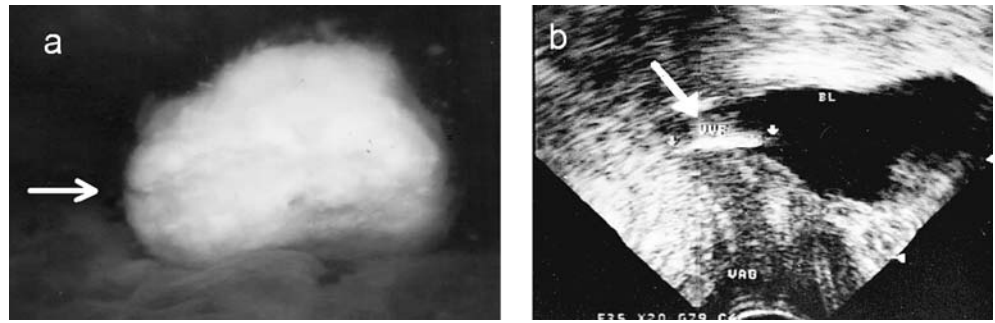
Discussion

Both animal and clinical investigations have revealed that intravesical foreign bodies, including all suture materials and even olive oil, might become an origin of stone formation [5, 6], and vesical stones can even erode through the endopelvic fascia into the vagina and form a vesicovaginal fistula [7]. Based on our patient's normal urinalysis, she had no urinary tract infection, and the etiology of the bladder stone was not similar to the case that Dalela et al. described [4]. In our patient, we considered that an inadvertent intravesical suture during hysterectomy had resulted in stone formation. Although the suture material was absorbed, the stone prevented the healing of the bladder mucosa and eroded through the bladder to the mucosa to form the vesicovaginal fistula.

Despite the fact that any intravesical suture could result in stone formation, we still suggest using quick-absorbable suture materials, such as chromic, during pelvic surgery, especially in the bladder base during hysterectomy to lower the risk of this complication. In patients with lower urinary tract symptoms after hysterectomy, cystoscopy is helpful in diagnosis, and vaginal ultrasound might detect overlooked lesions such as a second fistula or small stones. Once the fistula occurs, repair should be undertaken after resolving stone-induced edema and friability of the vesical wall [8].

W.-H. Chien · C.-C. Liang (✉)
Department of Obstetrics and Gynecology,
Chang Gung Memorial Hospital, Linkou Medical Center,
5, Fu-Shin Street, Kwei-Shan,
Taoyuan, Taiwan
e-mail: ccjoliang@cgmh.org.tw
Tel.: +886-3-3281200
Fax: +886-3-3288252

Fig. 1 **a** The bladder stone (*arrow*) embedded firmly in the bladder mucosa. **b** Vaginal ultrasound revealed a fistulous tract (*arrow*). (*BL* bladder, *VVF* vesicovaginal fistula, *VAG* vagina)



References

1. Tanski Z, Noll D, Leszczynski D (2001) Complications caused by nonabsorbable surgical sutures. *Ginekol Pol* 72(4):241–243 [Polish]
2. Woo HH, Rosario DJ, Chapple CR (1995) Stone formation on permanent suture material used previously in colposuspension. *Br J Urol* 76:139–140
3. Hadley HR (2002) Vesicovaginal fistula. *Curr Urol Rep* 3 (5):401–407
4. Dalela D, Goel A, Shakhwar SN, Singh KM (2003) Vesical calculi with unrepaired vesicovaginal fistula: a clinical appraisal of an uncommon association. *J Urol* 170(6 Pt 1):2206–2208
5. Morris MC, Baquero A, Redovan E, Mahoney E, Bannett AD (1986) Urolithiasis on absorbable and non-absorbable suture materials in the rabbit bladder. *J Urol* 135(3):602–603
6. Kato K, Hirata T, Suzuki K, Yoshida K, Suzuki S, Murase T (2005) Bladder stone caused by olive oil following TVT operation. *Nippon Hinyokika Gakkai Zasshi* 96(5):568–71 [Japanese]
7. Singh K (2002) An unusual complication of vesical stones. *Int Urogynecol J Pelvic Floor Dysfunct* 13(1):50–51
8. Mahapatra TP, Rao MS, Rao K, Sharma SK, Vaidyanathan S (1986) Vesical calculi associated with vesicovaginal fistulas: management considerations. *J Urol* 136(1):94–95