

Cem Dane · Murat Yayla · Banu Dane

## A foreign body (gossypiboma) in pregnancy: first report of a case

Received: 26 October 2005 / Accepted: 29 December 2005 / Published online: 28 February 2006  
© Springer-Verlag Berlin / Heidelberg 2006

**Abstract** The technical name for a surgical sponge left in the body of a patient is inadvertent “gossypiboma.” The word is derived from the Latin word *Gossypium* for cotton and from the Kiswahili word *boma* for “place of concealment.” These retained sponges were first seen as “textilomas,” but were renamed “gossypiboma” in 1978. The first case was reported by Wilson in 1884. These are rarely retrieved in the literature, because of legal complications. A higher incidence of retained laparotomy sponges has been reported in association with gynecological procedures. We report a case of gossypiboma in the 38th week of pregnancy that imitated an ovary neoplasm.

**Keywords** Gossypiboma · Retained surgical sponges · Pregnancy

### Introduction

The technical name for a surgical sponge left in the body of a patient is inadvertent “gossypiboma.” The word is derived from the Latin word *Gossypium* for cotton and from the Kiswahili word *boma* for “place of concealment.” These retained sponges were first seen as “textilomas,” but were renamed “gossypiboma” in 1978 [1]. The first case was reported by Wilson in 1884 (cited in [2]). These are rarely retrieved in the literature, because of legal complications. A higher incidence of retained laparotomy sponges has been reported in association with gynecological procedures. We report a case of gossypiboma in the 38th week of pregnancy that imitated an ovary neoplasm.

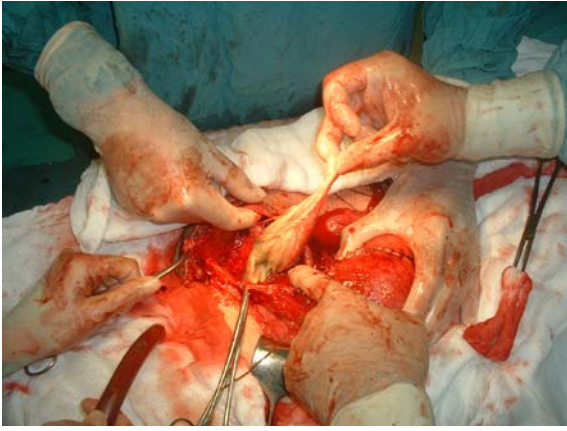
### Case report

A 27-year-old woman (G2P1) presented with abdominal pain at 38 weeks’ gestation. Her medical history included a Caesarean section 5 years before at another hospital. The patient had initially presented 4 weeks following the Caesarean section with abdominal pain, and a pelvic ultrasound at that time was normal. On examination, she had a mobile, obvious, firm, non-tender mass in the suprapubic area. During ultrasonography, an echoic mass surrounded by irregular hyperechoic areas and normal fetal anatomy in accordance with pregnancy was detected. A 2,900-g healthy male infant with an Apgar score of 9 at 38 weeks’ gestation was delivered. At the Caesarean operation, a piece of retained surgical towel was taken out and was seen surrounded by purulent material and the pseudocapsule formed by granulation tissue (Fig. 1). The abscess cavity was irrigated. Pathologic evaluation confirmed the presence of a foreign body in accordance with a sponge with surrounding inflammation and fibrosis. The patient made an uneventful recovery and was discharged home on the 5th postoperative day. At the follow-up 2 years after operation, the patient felt good and was completely recovered.

### Discussion

Gossypibomas generally occur following abdominal and gynaecological surgery. Although the true incidence is unknown, it was reported as being 1 in 100 to 3,000 for all surgical interventions and 1 in 1,000 to 15,000 for intraabdominal operations [3]. The surgical gauze is made out of cotton, which is rather inert and stimulates no specific biochemical reaction. When left in the body cavity, surgical sponges can create two types of foreign body reaction. The first type of response is exudative, with the resultant formation of an abscess with or without bacterial invasion. This reaction usually causes related clinical symptoms and signs shortly after surgery. The second type of response is aseptic with extensive adhesions

C. Dane (✉) · M. Yayla · B. Dane  
Department of Gynecology and Obstetrics,  
Haseki Education and Research Hospital,  
Istanbul, Turkey  
e-mail: cemdane@yahoo.com



**Fig. 1** Retained laparotomy towel in Caesarean section

and encapsulations resulting in a foreign body granuloma [4]. The septic complications are likely to present early during the postoperative period, whereas the aseptic encapsulations can disappear over a period of years, as in the case described here. The time between initial and repeated surgery varies from a few days to 20 years. Circumstances reported to explain operative loss of sponges are emergencies, urgency and haemorrhagic procedures, unexpected changes in the operation, time-consuming operations, large body habitus, and operations in anatomic regions that are difficult to reach [5]. The counting of packs used in long procedures, may also contribute, and additional counts are recommended when there are changes of the personnel in the operating theatre. The majority of the reported cases of gossypiboma occur when there is a normal pack count. The examination of the operative notes of the Caesarean and discussion with the original surgeon, in this case, did not indicate why or how a pack was retained. Probably, a pack was used during

closing and then not documented in the final account. Gossypibomas are generally not suspected and remain an accidental peroperative or postoperative finding. Treatment consists of thorough surgical exploration of the abdomen, removal of the gossypiboma, and drainage of the purulent fluid.

To our knowledge, our case is the first gossypiboma of occurring in a term pregnancy to be reported in the literature. Prevention of the gossypiboma is better than treatment. The current use of textile surgical materials soaked with radiopaque markers that are easily detected by the intraoperative radiological sifting when an incorrect count is suspected is a good method of prevention [5].

Counting sponges at the beginning of the operation, at closure of the peritoneum, and after wound dressing forms part of this attitude. Small sponges should not be used during laparotomy. Compresses should be used only intraperitoneally, one by one, mounted on a forceps. Before closing the peritoneum, the surgeon should explore the complete abdominal cavity, and sponges should not be used to facilitate closure.

## References

1. Williams RG, Bragg DG, Nelson JA (1978) Gossypiboma—the problem of the retained surgical sponge. *Radiology* 129:323–326
2. Le Ne'el JC, De Cussac JB, Dupas B, Letessier E, Borde L, Eloufir M (1994) Textilomas: a matter of 25 cases and review of the literature. *Chirurgie* 120:272
3. Gawande AA, Studdert DM, Orav EJ, Brennan TA, Zinner MJ (2003) Risk factors for retained instruments and sponges after surgery. *N Engl J Med* 348:229–235
4. Lauwers PR, Van Hee RH (2000) Intraperitoneal gossypibomas: the need to count sponges. *World J Surg* 24:521–527
5. Rajagopal A, Martin J (2002) Gossypiboma—“a surgeon's legacy”: report of a case and review of the literature. *Dis Colon Rectum* 45:119–120