

Ivan Mgaloblishvili · Manana Mgaloblishvili ·  
Ketevan Osidze · Natalia Beria

## Complex one-stop investigation of infertility: transvaginal hydrolaparoscopy

Received: 14 June 2006 / Accepted: 2 August 2006 / Published online: 17 October 2006  
© Springer-Verlag Berlin / Heidelberg 2006

**Abstract** One of the intensively discussed topics recently is investigation of infertile patients. A subject of particular interest is a new technique - transvaginal hydrolaparoscopy (TVHL), which has already found its place amongst other methods of infertility exploration. Transvaginal hydrolaparoscopy allows atraumatic investigation of reproductive organs in physiologic conditions, in ambulatory settings. Significant, for clinical practice, is the possibility of a combination of transvaginal hydrolaparoscopy with other methods of investigation - sonohysterosalpingography, hysteroscopy and salpingoscopy, which make possible integrated exploration of the reproductive system. Instillation of saline into the pelvic cavity through uterine tubes (or through puncture needle if needed) under ultrasonographic control and exposition of posterior fornix, allows better orientation in the pouch of Douglas, complex assessment of reproductive organs and determination of advisability of pelviscopy - the relatively invasive technique as well as thorough control of the safe access to the pouch of Douglas.

**Keywords** Fertiloscopy · Infertility ·  
Sonohysterosalpingography ·  
Transvaginal hydrolaparoscopy

Since Gordts et al. in 1998 have introduced the technique of transvaginal hydrolaparoscopy (TVHL), for the investigation of infertile women [1], interest to the vaginal route of genital tract exploration has been recommenced.

Introduction of more global concept of fertiloscopy: concurrent performance of pelviscopy, hysteroscopy, salpingoscopy and microsalingoscopy with chromoperturbation [2] allows for an increase in usefulness of infertility investigation and to optimize treatment strategy for infer-

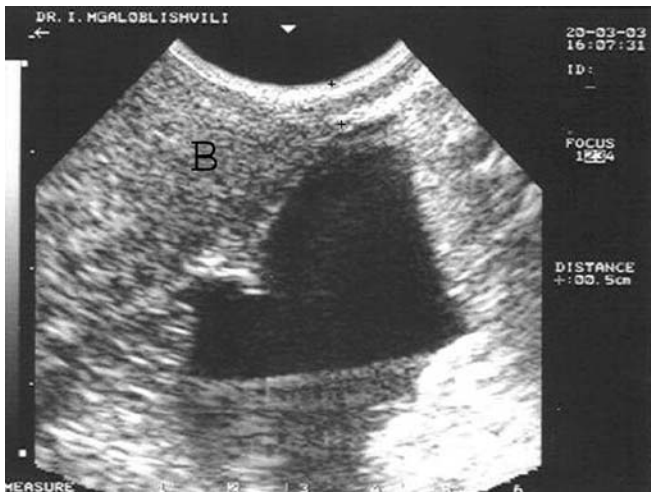
tility management with the consequent saving of time and costs. Introduction of this highly informative endoscopic technique into the format of one-stop investigation of infertility has become possible after the introduction of a new technique of atraumatic access to the pouch of Douglas via vaginal route using new instrumentations for transvaginal hydrolaparoscopy (TVHL) in the ambulatory settings [3, 4].

From April of 2002 till November of 2005 we have performed 837 fertiloscopies. As we described previously [5], TVHL with hysteroscopy and salpingoscopy is routinely performed in our clinic, in complex with sonohysterosalpingography and with extensive use of ultrasonographic control, in order to assess the future diagnostic insertion into the pouch of Douglas, as well as to ensure safety of this manipulation (instillation of warm saline for exposition of the posterior fornix of vagina).

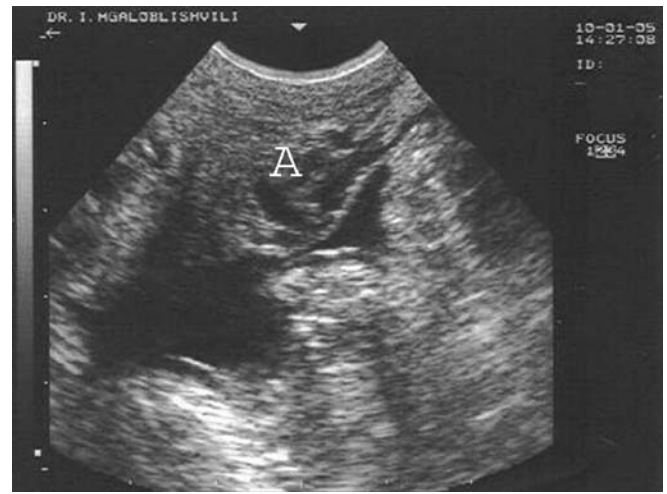The most difficult stage of TVHL is the introduction of instruments through the posterior fornix of the vagina into the pouch of Douglas. According to the data of various authors, access to the pouch of Douglas failed in 4.3-0% cases [1-4, 6-15]. Complications are expected when the patient has a retroverted uterus or in the presence of ovaries, uterine tubes, leiomyoma, bowel loops or varicose veins in the pouch of Douglas. Some authors consider such disposition as a relative/absolute contraindication to the procedure [1, 3, 4, 7, 12, 14, 16]. According to the data, the bowel trauma took place in 0.65% of procedures, but after the initial experience it has reduced to 0.25% [16]. In 50% of cases, bowel injury was estimated by the surgeon as avoidable. The development of safe techniques for insertion of instrument/s into the pelvic cavity, as well as determination of the capability and the necessity of performing pelviscopy is highly important.

As a matter of fact, nowadays there are several, similar systems of instruments for the access to the pouch of Douglas which differ in construction of the puncture needle (combined needle-trocar system with adapted Veress needle, and separate needle and trocar system). All systems have their advantages and disadvantages, but discussion of these topics is not the aim of this article. We would like to

I. Mgaloblishvili (✉) · M. Mgaloblishvili · K. Osidze · N. Beria  
Centre for Reproductive Medicine and Infertility, Surgery,  
16 Kavtaradze st.,  
Tbilisi, 0186, Georgia  
e-mail: cermi01@hotmail.com



**Fig. 1** Normal posterior fornix 5 mm in width



**Fig. 3** Behind the posterior fornix are visualized dilated vessels (a)

introduce some safe methods which enable the avoidance of complications to a greater extent, and to specify the possibility and rationality (reasonableness) of the performance of TVHL.

During performance of procedures we use Transvaginal hydrolaparoscopic kit (Circon ACMI, Stamford, CT) or Transvaginal hydrolaparoscopy set (Karl Storz, Tuttlingen, Germany). Ultrasonographic investigation/assistance was performed using Aloca SSD 650 with transvaginal probe with a frequency of 5.5 MHz, equipped with the puncture set.

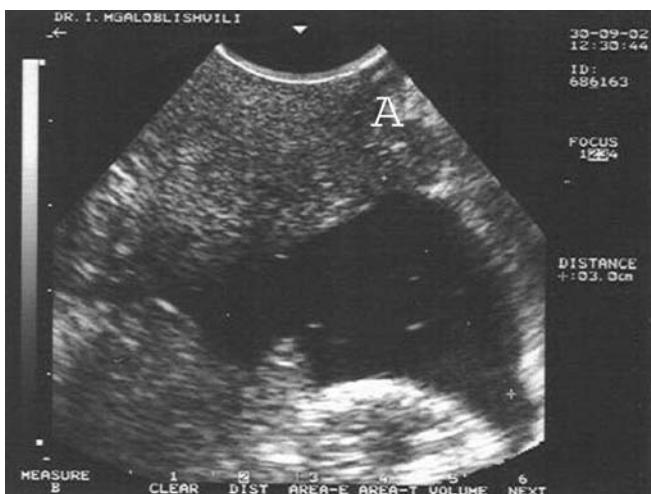During the process of preparation for laparoscopic investigation, detailed ultrasonography is performed with particular attention to the location of uterine corpus, uterine cervix and vagina, also to the state of posterior fornix of the vagina and the contents of the pouch of Douglas.

The first stage of the investigation is routine hysteroscopy, after which the pouch of Douglas is partially filled with saline (if at least one of the uterine tubes is patent).

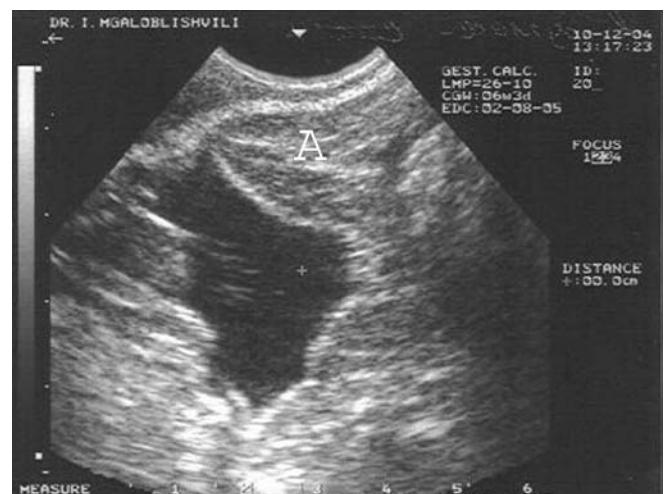The second stage is the routine sonohysterosalpingography during which by transtubal instillation of 60–200 ml of saline into the pelvic cavity, exposition of the posterior fornix of vagina is reached, which makes it possible, against a background of instilled fluid, to clearly visualize and assess the fornix (Figs. 1, 2, 3 and 4 determine the presence, the location and the characteristics of adhesions in the pouch of Douglas, presence of dilated vessels and presenting organs in minor pelvis. (Figs. 5, 6, 7 and 8).

In the case of non-patency of uterine tubes, which makes the instillation of saline into the pelvic cavity impossible, transvaginal puncture set is used under the ultrasonographic control, to allow exposition of the posterior fornix by instillation of water via an aspiration needle Fig. 7. The presence of follicular fluid during ovulation sometimes is quite enough for ultrasonographic orientation in the situation.

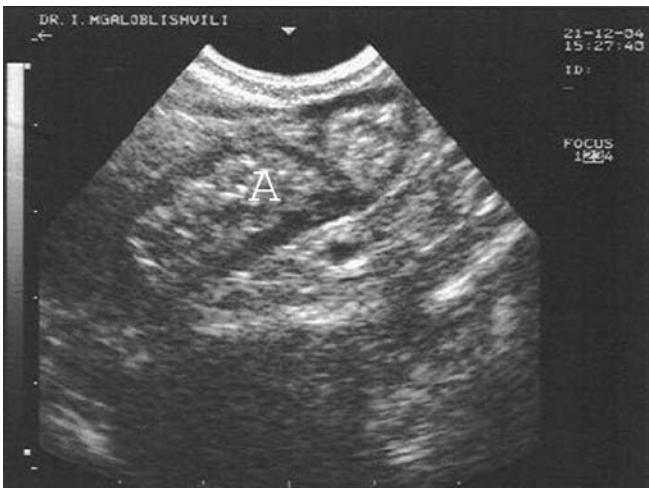
The third stage of investigation is the transvaginal hydrolaparoscopy: an insertion of laparoscopic instruments into the pelvic cavity is performed, if there have not been



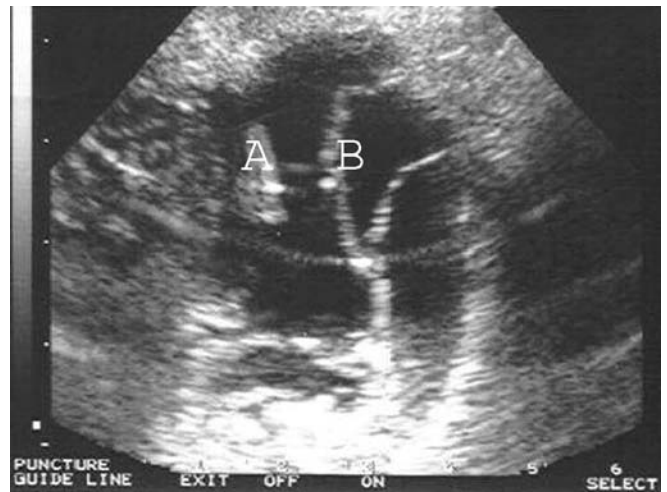
**Fig. 2** Evaluation of the puncture site. Depth of the free space is 30 mm, posterior fornix of vagina is thickened (a)



**Fig. 4** Thickened posterior fornix; echogenicity of the tissue corresponds to adipose tissue (a)



**Fig. 5** Complete obliteration of the pouch of Douglas, segment of intestinal loop (a)



**Fig. 7** After instillation of saline into pelvic cavity via puncture needle (a) several dense, connecting adhesions are visualized (b)

revealed contraindications or reasons of TVHL cancellation (for example hydrosalpinges-Fig. 8) at previous stages of investigation. These conditions are:

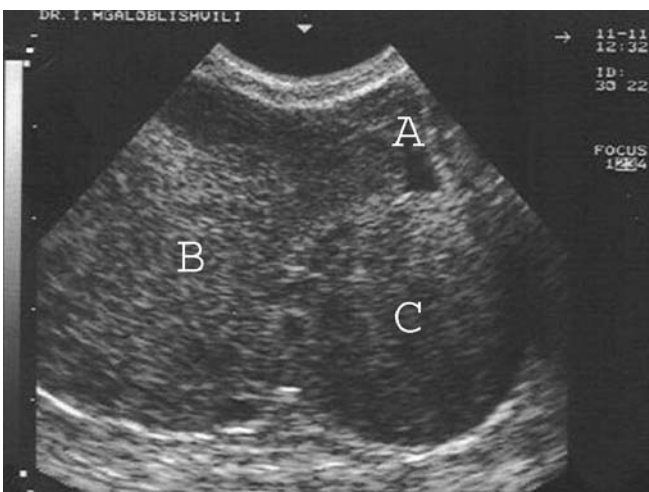
1. Complete obliteration of the pouch of Douglas Fig. 5.
2. Thickening of posterior fornix, often with uneven echo structure and width Fig. 2, with the visualized dilated vessels Fig. 3, sometimes with presence of retro cervical endometriosis or varicose veins, adipose structure behind the posterior fornix or vagina Fig. 4.
3. Intensive adhesions in the pouch of Douglas Fig. 7.
4. Localization of fixed organs of minor pelvis into the pouch of Douglas: one or both ovaries, uterine tube/s Fig. 8, intestinal loops Fig. 5, myomatous node or uterine corpus Fig. 6.
5. Bilateral hydrosalpinges Bilateral Fig. 8.

Among the investigated 837 infertile women, in 6 cases was detected suspicious pathology on atypical alterations, thus further stages of investigation were postponed until an appropriate differential diagnosis is obtained.

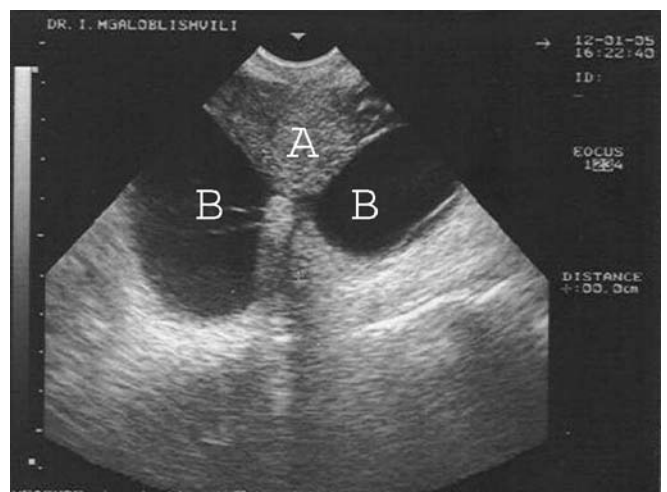
Results of the next stage, sonohysterosalpingography for the remaining 831 women are summarized in Table 1.

After the stages of hysteroscopy and sonohysterosalpingography, transvaginal hydrolaparoscopy was performed in 702 of the 837 women. An extent of exploration was determined during the procedure, after considering advisability and possible safety of conducting different interventions (Fig. 9 Algorithm of management). In 135 (16.1%) women out of 837 TVHL was cancelled or postponed. We have not noted any complications during performed investigations.

Hydrosalpinges of at least one of the tubes, does not represent contraindication for performing transvaginal hydrolaparoscopy per se (if it is not obliterating the pouch of Douglas), but often on the stage of sonohyster-



**Fig. 6** Myomatous node in the pouch of Douglas: free saline (a), myomatous node (b), uterine corpus (c)



**Fig. 8** Bilateral hydrosalpinges (b) fixed in the pouch of Douglas, uterus (a)

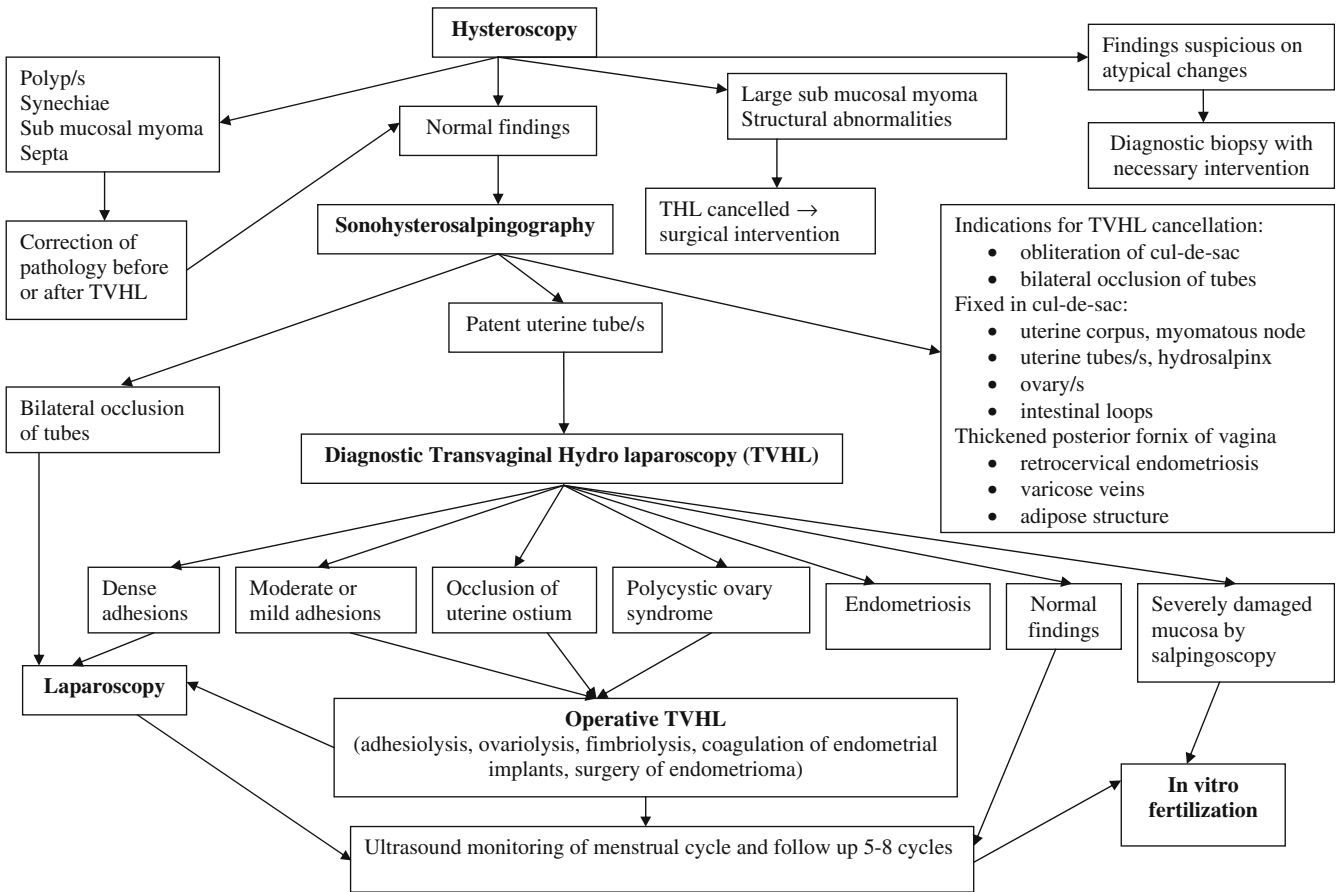
**Table 1** Frequency of different conditions by sonohysterosalpingography which were considered as reasons for TVHL cancellation

Total number of patients after the hysteroscopy-831	Pathologic findings		Patients with cancelled TVHL		
	No	%	No	%	
Bilateral proximal obstruction of tubes	19	2.28	12	1.44	
Bilateral hydrosalpinges	26	3.12	26	3.12	
Extensive adhesions in the pouch of Douglas	140	16.8	47*	5.65	
Located in the pouch of Douglas	myomatous node/ hyperretroflexion ovary/s	7	0.84	5	0.6
	uterine tube/s, hydrosalpinges	11	1.32	6	0.72
	fixed intestinal loops	2	0.24	2	0.24
Thickened posterior fornix of vagina	retro cervical endometriosis	21	2.52	21	2.52
	dilated vessels	4	0.48	4	0.48
	adipose structure	4	0.48	4	0.48
		2	0.24	2	0.24

\*Strategy was determined on the basis of the extent of adhesions.

osalpingography/hysteroscopy the need for the transvaginal hydrolaparoscopy vanishes, as a treatment strategy of infertility becomes evident (Fig. 9 Algorithm of management). On the basis of already discovered findings it is possible to switch to the accepted interventions for infertility management. This includes either restoration of natural fertility - reconstructive surgery of the uterine tubes or creation of optimal conditions for IVF (proximal obstruction of tubes, salpingectomy etc) [17].

Ultrasonographic control during procedure of transvaginal hydrolaparoscopy not only allows an evaluation of the proximal parts of tubes which in complex increases informativeness of the investigation, but also gives a possibility to visualize existence of adhesions in the pouch of Douglas-together with the introduction of the trocar system. However it is not sufficient enough to assess the



**Fig. 9** Algorithm of management

role of adhesions in infertility as this method is not able to access the fimbrial-ovarian area- a key functioning part of the reproductive tract.

Thus, we present the investigation of infertility which includes: hysteroscopy, sonohysterosalpingography with instillation of fluid into the pelvic cavity (if necessary via puncture needle) under ultrasonographic control, which provides exposition of the posterior fornix and orientation in the pouch of Douglas, hydropelviscopy with dye chromopertubation and salpingoscopy. Such a format of investigation makes it possible for amore complex evaluation of reproductive system and determination of advisability of performance of transvaginal hydrolaparoscopy - a relatively invasive procedure with more intensive control of safety of the access to the pouch of Douglas.

---

## References

- Gordts S, Campo R, Rombauts L, Brosens I (1998) Transvaginal hydrolaparoscopy as an outpatient procedure for infertility investigation. *Hum Reprod* 13(1):99–103
- Watrelet A, Dreyfus JM, Andine JP (1999) Evaluation of the performance of fertiloscopy in 160 consecutive infertile patients with no obvious pathology. *Hum Reprod* 14(3):707–711
- Gordts S, Campo R, Puttemans P, Verhoeven H, Gianaroli L, Brosens J, Brosens I (2002) Investigation of the infertile couple: a one-stop outpatient endoscopy-based approach. *Hum Reprod* 17(7):1684–1687
- Brosens I, Campo R, Puttemans P, Gordts S (2002) One-stop endoscopy-based infertility clinic. *Curr Opin Obstet Gynecol* 4(4):397–400
- Mgaloblishvi IB, Osidze KR, Mgaloblishvili MB, Beria NE (2002) Transvaginal hydrolaparoscopy-practical application to the infertility. *Russian J Hum Reprod* 5:6–9
- Gordts S, Campo R, Brosens I (2000) Office transvaginal hydrolaparoscopy for early diagnosis of pelvic endometriosis and adhesions. *J Am Assoc Gynecol Laparosc* 7(1):45–49
- Darai E, Dessolle L, Lecuru F, Soriano D (2000) Transvaginal hydrolaparoscopy compared with laparoscopy for the evaluation of infertile women: a prospective comparative blind study. *Hum Reprod* 15(11):2379–2382
- Dechaud H, Ali Ahmed SA, Aligier N, Vergnes C, Hedon B (2001) Does transvaginal hydrolaparoscopy render standard diagnostic laparoscopy obsolete for unexplained infertility investigation? *Eur J Obstet Gynecol Reprod Biol* 94(1):97–102
- Shibahara H, Fujiwara H, Hirano Y, Suzuki T, Obara H, Takamizawa S, Idei S, Sato I (2001) Usefulness of transvaginal hydrolaparoscopy in investigating infertile women with Chlamydia trachomatis infection. *Hum Reprod* 16(8):1690–1693
- Nawroth F, Foth D, Schmidt T, Romer T (2001) Results of a prospective comparative study of transvaginal hydrolaparoscopy and chromolaparoscopy in the diagnostics of infertility. *Gynecol Obstet Invest* 52(3):184–188
- Casa A, Sesti F, Marziali M, Piccione E (2002) Transvaginal hydrolaparoscopy vs. conventional laparoscopy for evaluating unexplained primary infertility in women. *J Reprod Med* 47(8):617–620
- Jonsdottir K, Lunderoff P (2002) Transvaginal hydrolaparoscopy: a new diagnostic tool in infertility investigation. *Acta Obstet Gynecol Scand* 81(9):882–885
- Campo R, Gordts S, Brosens I (2002) Minimally invasive exploration of the female reproductive tract in infertility. *Reprod Biomed (Online)* 4 (Suppl 3):40–45
- Watrelet A, Nisolle M, Chelli H, Hocke C, Rongieres C, Racinet C (2003) International Group for Fertiloscopy Evaluation. Is laparoscopy still the gold standard in infertility assessment? A comparison of fertiloscopy versus laparoscopy in infertility. Results of an international multicentre prospective trial: the 'FLY' (Fertiloscopy-Laparoscopy) study. *Hum Reprod* 18(4):834–839
- Moore ML, Cohen M (2001) Diagnostic and operative transvaginal hydrolaparoscopy for infertility and pelvic pain. *J Am Assoc Gynecol Laparosc* 8:393–397
- Gordts S, Watrelet A, Campo R, Brosens I (2001) Risk and outcome of bowel injury during transvaginal pelvic endoscopy. *Fertil Steril* 76(6):1238–1241, Dec
- Sacks G, Trew G Reconstruction, destruction and IVF: dilemmas in the art of tubal surgery. *BJOG* 11(11):1174