

Hermann J. Pfannenstiel (1862–1909) and the Pfannenstiel incision

M. Thiery

© Springer-Verlag 2009

The name Pfannenstiel remains eponymously linked to the “*suprasympphysäre Fascienquerschnitt*”, the supra-symphyseal fascia crosscut laparotomy technique that was published by this German gynaecologist in 1900 and which became widely applied by gynaecologists and urologists.

Hermann Johannes Pfannenstiel was born on 28 June 1862 in Berlin, the son of a bank manager [1–4] (Fig. 1).



Fig. 1 Hermann Johannes Pfannenstiel

M. Thiery
Foundation Jan Palfyn and Museum of Medical History,
Ghent, Belgium

M. Thiery (✉)
Aan de Bocht 6,
9000 Ghent, Belgium

He studied medicine in that city and graduated in 1885. During the next two years, he worked as an assistant to Dr. Joseph Pauly (1843–1916), the Chief Surgeon of the City Hospital in Posen, who became his tutor. Subsequently, Pfannenstiel specialized in gynaecology in Breslau with the renowned Professor Heinrich Fritsch (1844–1915), the founder of the *Zentralblatt für Gynäkologie*, a leading

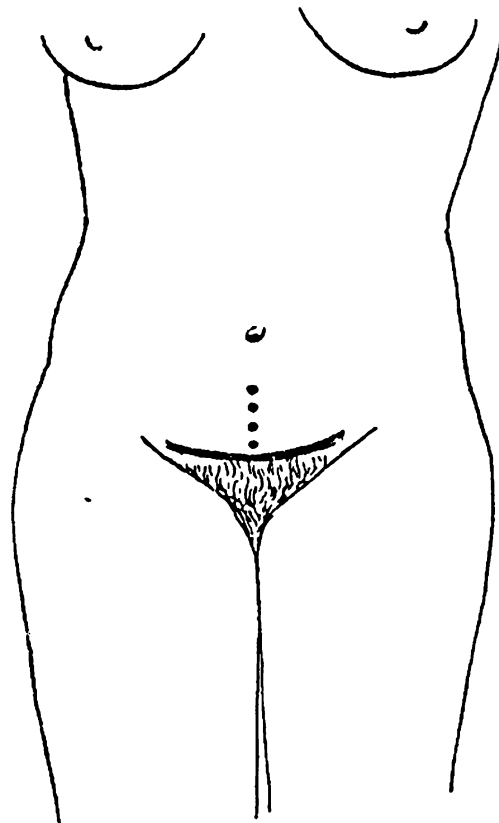


Fig. 2 Skin incision according to the Pfannenstiel technique (Pfannenstiel, 1900)

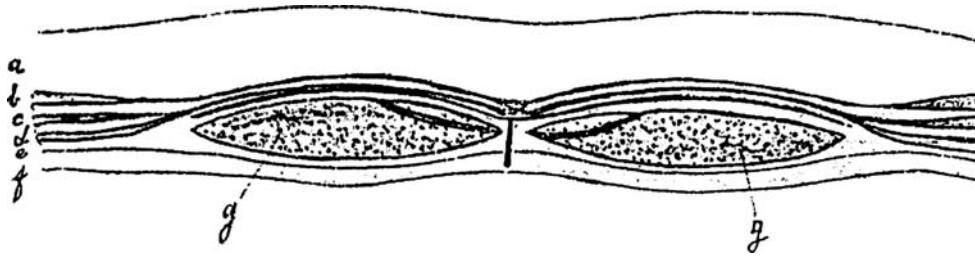


Fig. 3 Topographic anatomy of the ‘suprasympphysäre Fascienquerschnitt’ (a: cutis and subcutis; b = m. obliquus externus; c: m. obliquus internus; d: m. transversus; e: fascia transversa; f: peritone-

um; g: mm. recti abdominis). The horizontal lines and the vertical line indicate, respectively, the loosening of the aponeuroses of the mm. recti and the incision of the linea alba (Pffannenstiel, 1900)

medical journal. Under the Professor’s tutelage, he qualified in 1890 with a study on pseudo-mucus and the pseudo-mucinous tumours [5].

Six years later, Dr. Pffannenstiel was appointed “*Primarius*”, Chief Surgeon, of the gynaecology department at the large *Elisabetherinnen Krankenhaus*, the Hospital of the Sisters of St. Elisabeth in Breslau, and offered the position of lecturer at the city’s university. In 1902, he succeeded Hermann Löhlein (1847–1901) in Giessen as ‘*ordinarius*’ in obstetrics and gynaecology and became director of the *Frauenklinik*, the Women’s hospital, and the associated midwifery school. In 1907, he accepted the equivalent chair in Kiel and there succeeded Prof. Emeritus Richard Werth (1850–1918). In spite of his extensive duties and commitments, Prof. Pffannenstiel found time to demonstrate his laparotomy technique in the United States, London, and Paris. Alas, the promising career of this remarkable man was tragically cut short. He pricked his finger during the operation on a patient suffering from a tubo-ovarian abscess and some days later died of sepsis.

Hermann J. Pffannenstiel had built a reputation as an excellent clinician, surgeon, and lecturer. His multiple contributions to pathological anatomy and the clinical analysis of the tumours of the female genital tract survived their author and his monograph about the papillary ovarian tumours remains a classic [6].

Pffannenstiel was the first to give an accurate description of the *icterus gravis neonatorum* [7] but it is with his laparotomy technique that his name will forever be associated [8]. Until the end of the 19th century, the longitudinal-median laparotomy technique was exclusively applied, whereby all tissue layers are incised along the mid-line. A feared complication was the rupturing of the scar tissue. In order to avoid this type of hernia, Prof. Otto Küstner (1848–1931) in 1896 proposed to cut diagonally into the skin and subcutaneous fatty tissue above the pubic symphysis and to treat the deeper tissue layers in the usual manner [9]. But in itself, Küstner’s “*supra-symphysäre Kreuzschnitt*”—his supra-symphyseal crosscut—did not bring the desired result,

since “Die Hernie entsteht in Folge mangelnder Verwachsung der Fascien bzw. der Aponeurosen”, so that “eine gute Vereinigung der darüber liegenden Haut keinen Schutz gegen die Hernie gewärt” [8], and thus the dreaded problem of the possible occurrence of herniation remained unresolved. Because of this continuing concern, Pffannenstiel decided to thoroughly change Küstner’s technique, to the extent that the “nicht nur die Haut, sondern auch die gesammelte Fascienschnitt quer durchtrennte und nun erst—nach Ablösung der Fascie gegen den Nabel hin—Muskulatur und Bauchfell längs spaltete, um so die Aponeurose im Bereiche der Längsschnittwunde des Leibes vollkommen intakt zu erhalten [8]”. In order to clearly distinguish his technique from that of his predecessor, he called it “*suprasympphysäre Fascienquerschnitt*”. He described the technique for the first time in 1900 and elucidated the anatomical basis (Figs. 2 and 3). Based on the results of 51 cases, he concluded that the new method was efficient and effective. His technique was rapidly adopted on the European continent by fellow gynaecologists, who were generally regarded contemptuously by the general surgeons. They would, as it were, make the Pffannenstiel incision their trademark. In contrast, in Great Britain as in the United States, it took until after the end of the Second World War before this incision was generally accepted. Although the reason for this reluctance is not entirely clear, it is certain that the esthetic element played a definite role. Following the introduction of the two-piece bathing suit, the Pffannenstiel-incision was called “Bikini-cut”, as it became known.

References

1. Fritsch H (1909) Johannes Pffannenstiel. *Zentralblad Gynäkol* 33
2. Pffannenstiel HJ (1909) Obituary notices. *J Obstet Gynaecol Brit Emp* 16:274
3. Fischer I (1962) *Biographisches Lexikon der hervorragenden Aertze der letzten fünfzig Jahre*. Urban u. Schwarzenberg, Munich
4. Easton L (1984) Hermann Johannes Pffannenstiel (1862–1909). *Br J Obstet Gynaecol* 91:538

5. Pfannenstiel HJ (1890) Ueber die Pseudomucine der cystischen Ovariengeschwülste. T. Engelhardt, Leipzig
6. Pfannenstiel HJ (1895) Ueber die papillären Geschwülste des Eierstocks. Anatomische und klinische Untersuchungen zur Klärung der Frage ihrer Malignität. Arch Gynäkol 48:507
7. Pfannenstiel HJ (1908) Ueber den habituellen Ikterus der Neugeborenen. Münch Med Wochenschr 55:2169 2233
8. Pfannenstiel HJ (1900) Ueber die Vortheile des suprasymphysären Fascienquerschnitts für die gynäkologischen Köliotomien, zugleich ein Beitrage zu der Indikationstellung der Operationswege. Samm Klin Vorträge (Leipzig) 268:1735
9. Kuestner O (1896) Der suprasymphysäre Fascienquerschnitt, eine Methode der Coeliotomie bei wenig umfangreichen Affektionen der weiblichen Beckenorgane. Monatsschr Geburtsh Gynäkol 4:14