

Rare case of schwannoma in the rectovaginal septum

I. Anev · A. Clarke · C. Lee-Elliott · T. Carpenter

Received: 26 April 2010 / Accepted: 12 May 2010 / Published online: 11 June 2010
© Springer-Verlag 2010

Introduction

This is a case report of a patient with very rare location of schwannoma. The article explores the management approach applied to diagnose the condition and the way it was treated. In the discussion part, we outline aspects of the natural history of the tumour, its more common presentations in and outside the field of gynaecology and follow-up. We believe the case report would appeal to a wide audience of readers of the *Gynecological Surgery Journal*.

Case presentation

A 36-year-old lady presented with a 2-year history of painful defaecation and a painful nodular swelling in the posterior vaginal wall that increased in size prior to and during menstruation. She had no other pelvic pain, notably no dysmenorrhea or dyspareunia, but did have dyschesia when the nodule was enlarged. Her menstrual cycle was normal with a regular 28-day cycle. Previously, she had had two term deliveries, one by caesarean section and the other by vaginal delivery.

At presentation, she was using a progesterone-only pill for contraception but had previously used the combined oral contraceptive pill, which apparently improved her symptoms.

Combined rectal and vaginal examination revealed the presence of a 2-cm nodular mass between the vagina and

rectum approximately 5 cm from the posterior forchette. It was non-tender at that stage and did not appear fixed to the rectum or vagina.

In view of the cyclical nature of the lesion and previous response to the combined oral contraceptive pill, this was re-started in a tri-cyclical fashion. During this time, the nodule reduced in size and the pain ceased.

Magnetic resonance imaging (MRI) scan demonstrated a 10-mm well-circumscribed elliptical lesion of homogenous intermediate to high signal, arising within the anterior rectal wall immediately above the ano-rectal junction. It did not have the expected appearance of endometriotic nodules which are usually of low signal and which often have fibrotic stranding surrounding them. There was no invasion or in-drawing of adjacent structures which would be expected with rectovaginal endometriosis and a gastrointestinal stromal tumour was considered a possibility.

Diagnostic laparoscopy equally showed no endometriosis.

Following a discussion with the patient, it was decided to excise the lesion, which was undertaken by a gynaecologist and colorectal surgeon via a vaginal approach.

Following infiltration of the area with Marcain and adrenaline, the posterior vaginal wall was opened over the nodule. The nodule was carefully dissected out, leaving a 1-cm defect in the muscularis layer of the rectum. The rectal mucosa was intact and the muscularis layer was repaired with three interrupted 3.0 PDS sutures. The patient made a good recovery and was discharged home the next day.

Histopathology of the lesion demonstrated a circumscribed lesion made up of spindle cells arranged in interlacing fascicles and bundles. Standard immunological stains were used and immunohistochemistry showed positivity with S100 while the lesion was negative for actin, desmin, ER, PR, CAM5.2, and CD10. The appearance of the lesion was consistent with schwannoma without

I. Anev (✉) · A. Clarke · C. Lee-Elliott · T. Carpenter
Poole Hospital NHS Foundation
Trust—Obstetrics and Gynaecology,
Longfleet Rd,
Poole BH15 2JB, UK
e-mail: dranev@doctors.org.uk

atypical features. The tumour was possibly originating from the rectovaginal plexus and was negative both for oestrogen and progesterone receptors.

Discussion

A schwannoma (also known as a neuroma, neurilemmoma [1], neurinoma, neurolemmoma, and Schwann cell tumour) is a benign tumour composed of Schwann cells, which normally produce the insulating peripheral nerves sheath myelin [2]. They are usually benign with less than 1% undergoing malignant change into neurofibrosarcomas.

The symptoms of the tumour depend mainly on the location. While certain locations are common (e.g., acoustic nerve), abdominal or perineal locations are rare.

Schwannomas affecting the rectovaginal septum are very rare. To our knowledge, there had been only two reported cases in this location (the last being nearly 50 years ago) [3, 4]. Schwannomas of the pelvis and vagina have been reported more recently but these are still extremely rare [1, 5, 6]

Due to its initial presentation, deep pelvic endometriosis was considered to be the likely initial diagnosis. In its support was the cyclical swelling of the tumour; however, the negative laparoscopy and MRI findings made this less likely and a more unusual tumour needed to be considered.

Due to its rare location, there is limited data regarding the natural history of schwannomas with rectovaginal location. It is logical to assume that, as most benign tumours, schwannomas would enlarge if left untreated. In a systematic review of 1,340 patients with schwannomas within a vestibular location, Youshimoto describes a mean annual growth rate of 1.2 mm/year [7]. It is of interest that pregnancy has been associated as a predisposing factor for the accelerated growth of certain schwannomas, i.e., in the orbital space which is believed to be secondary to haemorrhage within the tumour [8].

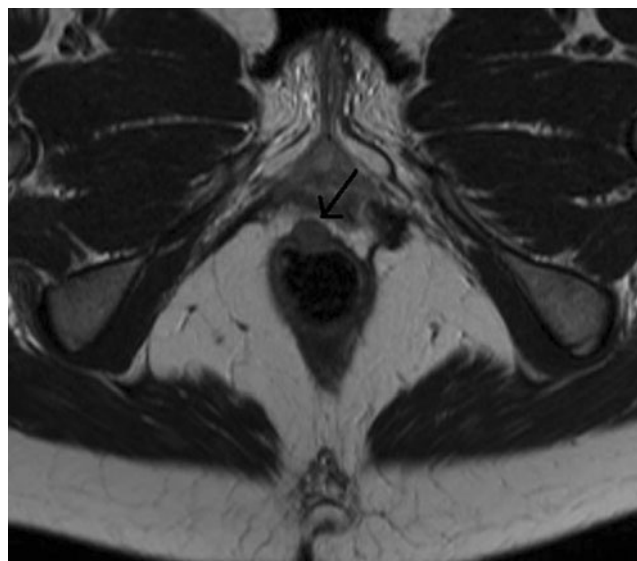
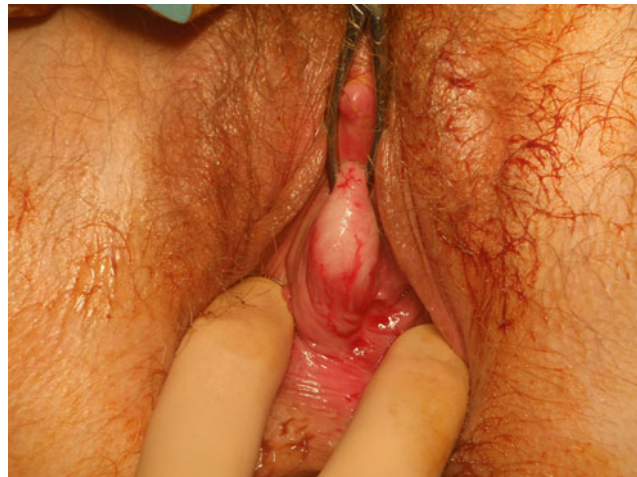The cyclical pattern of enlargement and pain in this case, along with the very effective use of the combined oral contraceptive, clearly raised the strong possibility of endometriosis although clearly the MRI and lack of any other disease in the pelvis did not support this. Of note, however, cyclical enlargement and discomfort has been documented for vaginal/vulval schwannomas which would probably explain the behaviour of the nodule in this case [9].

The lack of oestrogen and progesterone receptors makes it difficult to explain why these lesions can respond to ovarian/placental hormones but clearly in this and other cases this does occur. It is probable therefore that these hormones act via another mechanism.

In view of the benign nature of these lesions, and the fact that it has been completely excised, no further follow-up is required.

Conclusion

This case demonstrates that not all cyclical lesions are gynaecological in origin and, although rare, schwannoma should be considered in the differential diagnosis of atypical rectovaginal lesions.



Declaration of interest The authors report no conflicts of interest. The authors alone are responsible for the content and writing of the paper.

References

1. James W, Berger T, Elston D (2005) *Andrews' diseases of the skin: clinical dermatology*, 10th edn. Saunders

2. Obeidat BR, Amarin ZO, Jallad MF (2007) Vaginal schwannoma: a case report. *J reprod Med* 52(4):341–342
3. A neurilemmoma (schwannoma) in the rectovaginal septum (1961) *Bull Soc Belge Gynecol Obstet* 131:381–385
4. Ugeskr Laeger (1952) Two neurinomas of the stomach and a neurinoma of the rectovaginal septum. 114(8):246–247
5. Inoue T, Kato H, Yoshikawa K, Adachi T (2004) Retroperitoneal schwannoma bearing at the right vaginal wall. *J Obstet Gynaecol Res* 30(6):454–457
6. Ueda M, Okamoto Y, Ueki M (1996) A pelvic retroperitoneal schwannoma arising in the right paracolpium. *Gynaecol Oncol* 60(3):480–483
7. Yoshimoto Y (2005) Systematic review of the natural history of vestibular schwannoma. *J Neurosurg* 103(1):59–63
8. Sugo N, Yokota K, Nemoto M, Hatori T, Kano T, Goto S, Seiki Y (2007) Accelerated growth of an orbital schwannoma during pregnancy. *J Neuroophthalmol* 27(1):45–47
9. Vern L, Katz (2007) *Comprehensive gynaecology*, 5th edn. Chapter 18. Mosby, Elsevier