

Retained term tubal ectopic pregnancy

Ismail A. Al-Badawi · Togas Tulandi

Received: 3 April 2010 / Accepted: 9 June 2010 / Published online: 22 June 2010
© Springer-Verlag 2010

Keywords Ectopic pregnancy · Tubal pregnancy · Term tubal ectopic pregnancy

Background

Tubal ectopic pregnancy accounts for approximately 1% of all pregnancies. Term tubal pregnancy, however is extremely rare. Review of the literature revealed that at least over 12 cases of term tubal pregnancy have been reported. Most of them were published in the 1950s [1–11]. The most recent article on this subject was published in 2007 [12]. We present a case of a tubal pregnancy with a macerated fetus inside.

Method

Patient was a 32-year-old woman, G3P2, with an abdominal mass, and amenorrhea of 2-year duration. She lived in a rural area with no medical facility. Knowing about the upcoming visit of a consulting gynecologist (IAB), she and other potential patients gathered at the entrance of a

hospital in Marwa City, Cameroon to be selected by local nurses for examination. Physical examination revealed a hard abdominal mass filling almost the entire abdominal cavity. Due to the limited facilities, medical imaging was not available. At laparotomy, we found a macerated fetus in a hugely distended left fallopian tube. The uterus was normal and separated from the tube. The right tube and ovaries were normal. The fetus was delivered and a left salpingectomy was performed.

Findings

Our patient underwent surgery at a small hospital with limited facilities in Cameroon. The hospital has no imaging or pathology services. In any event, our operative finding was clear. The fetus was inside an extremely distended and thin-walled fallopian tube (Fig. 1). A differential diagnosis in this case would include pregnancy in a rudimentary uterine horn, abdominal pregnancy, or healed ruptured term uterine pregnancy. We performed a thorough intra-operative examination and found no evidence of any uterine anomaly whatsoever. In addition, the uterus was completely normal and the abdominal cavity was free from any adhesions.

The only information that could be incorrect is the duration of pregnancy. She gave a history of amenorrhea of 2-year duration. This was obtained through two translators; one of them was a medical student. A recall bias is a possibility. Patient could not provide any information about the feeling of fetal movement.

The finding of a macerated fetus suggests that fetal death occurred long before her presentation to the hospital. In addition, she had never experience labor pain. One of the

Declaration of interest The authors report no conflicts of interest. The authors alone are responsible for the content and writing of the paper.

I. A. Al-Badawi (✉)
Department of Obstetrics and Gynecology,
King Faisal Specialist Hospital & Research Center,
3354, Riyadh 11211, Saudi Arabia
e-mail: i_albadawi@yahoo.com
e-mail: ibadawi@kfshrc.edu.sa

T. Tulandi
McGill University,
Montreal, QC, Canada

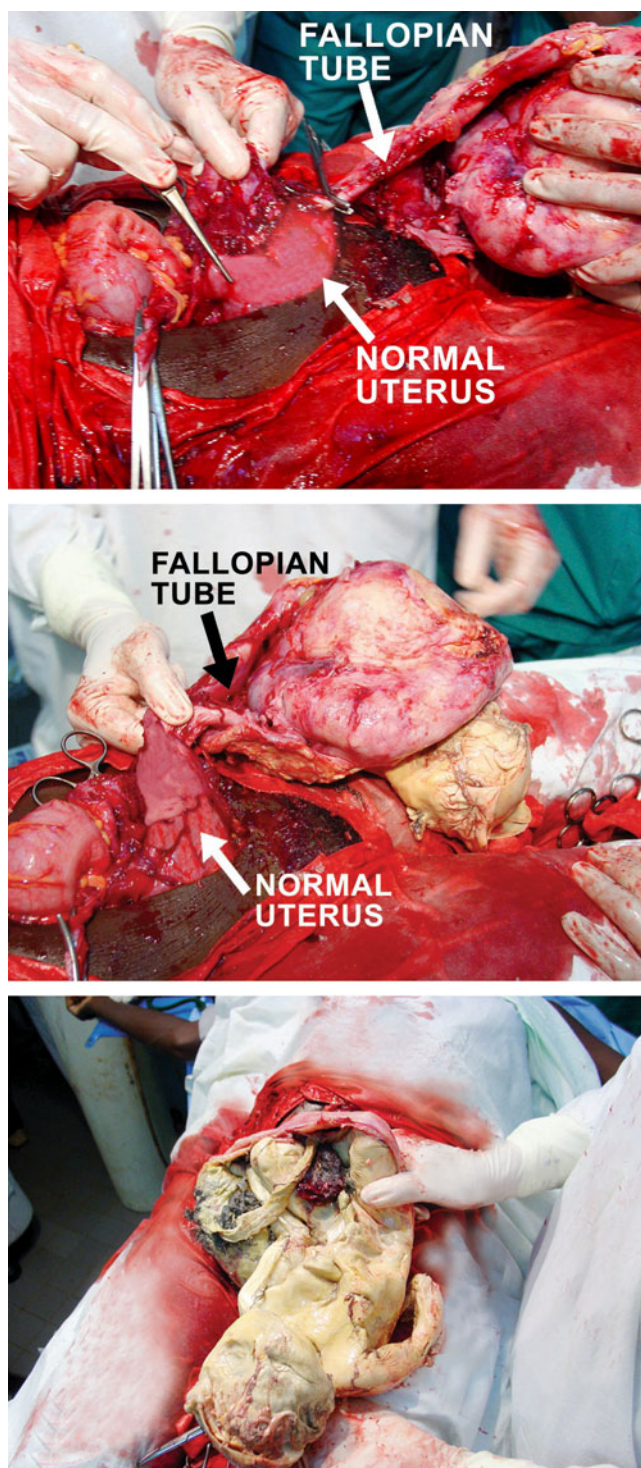


Fig. 1 A macerated fetus in a hugely distended left fallopian tube. The uterus was normal and separated from the tube

risks of retained fetal death is the occurrence of disseminated intravascular coagulation that can occur in 12.7% in cases [13]. Despite living in a destitute place with limited

medical facilities, our patient did not appear to experience any coagulation disorder.

Over three million stillbirths occur each year worldwide [14, 15] If the rate of stillbirths in the US is 6.2 of 1,000 total births [16], the rates in developing countries are much higher; for example the still birth rate in Congo is 30 of 1,000 births [17, 18] Our patient had had a macerated fetus inside the fallopian tube.

Conclusion

Our case report suggests that although extremely rare, term tubal pregnancy can still be encountered in a place with limited medical facilities.

References

1. Waltz JH (1950) Term tubal pregnancy. A case report. *North Carolina. Med J* 11:634–637
2. Myelin TW, Randall LM (1951) Intratubal term pregnancy without rupture: review of the literature and presentation of diagnostic criteria. *Am J Obstet Gynecol* 61:130
3. O'Connell CP (1952) Full-term tubal pregnancy. *Am J Obstet Gynecol* 63:1305–1311
4. Frachtman KG (1953) Unruptured tubal term pregnancy. *Am J Surg* 85:161
5. Gustafson GW, Bowman HE, Stout FE (1953) Extrauterine pregnancy at term. *Obstet Gynecol* 2:17
6. Vaish R (1959) Term tubal pregnancy with survival of mother and infant. *Am J Obstet Gynecol* 77:1309–1311
7. Kent JF (1963) Term tubal pregnancy. *Aust NZ J Obstet Gynaecol* 41:139–141
8. Marais OA (1962) Full-term tubal pregnancy with retention of skeleton for ten months. *S Afr Med J* 36:327–328
9. Schokman CM (1966) Advanced tubal pregnancy: a case of survival of mother and baby. *Aust NZ J Obstet Gynaecol* 6:171, 13
10. Maas DA, Slabber CF (2007) Diagnosis and treatment of advanced extrauterine pregnancy. *S Afr Med J* 1975:49
11. Augensen K (1983) Unruptured tubal pregnancy at term with survival of mother and child. *Obstet Gynecol* 61:259–260
12. Huang SC, Hsu TY (2007) Term tubal pregnancy with a live born and healthy baby. *Pediat Dev Pathol* 10:69–71
13. Angelov A (1989) Intravascular coagulation in relation to pregnancy and delivery. *Zentralbl Gynäkol* 111(17):1169–1175
14. Say L, Donner A, Gulmezoglu AM et al (2006) The prevalence of stillbirths: a systematic review. *Reprod Health* 3:1
15. Stanton C, Lawn JE, Rahman H et al (2006) Stillbirth rates: delivering estimates in 190 countries. *Lancet* 367:1487
16. MacDorman MF, Kirmeyer S (2009) Fetal and perinatal mortality, United States, 2005. *Natl Vital Stat Rep* 57:1
17. McClure EM, Nalubamba-Phiri M, Goldenberg RL (2006) Stillbirth in developing countries. *Int J Gynaecol Obstet* 94:82
18. McClure EM, Wright LL, Goldenberg RL et al (2007) The global network: a prospective study of stillbirths in developing countries. *Am J Obstet Gynecol* 197:247