Gynecol Surg (2007) 4: 53–56
DOI 10.1007/s10397-006-0212-2

CASE REPORT

Andrea Tinelli · Antonio Malvasi · Raffaele Tinelli · Carlo Cavallotti · Francesco G. Tinelli

Conservative laparoscopic treatment of post-caesarean section bladder flap haematoma: two case reports

Received: 10 April 2006 / Accepted: 24 May 2006 / Published online: 19 July 2006

Abstract A bladder flap haematoma (BFH) is an unusual complication of caesarean section and results from bleeding at the uterine suture. This haematoma arises between the posterior bladder wall and lower uterine segment. On ultrasonographic examination, it appears as a solid area or a complex mass with clean walls and reinforcement of the distal echoes. No clear and defined protocol exists for clinical management of BFH; in more severe cases, when the blood loss is continuous or if it transforms into an abscess, it needs non-standardized surgical treatment. When surgery is performed, usually the BFH is only drained, reserving hysterectomy for severe uterine necrosis, myometritis or abscess formations. In our experience, we have performed two conservative laparoscopic treatments with drainage of the BFH.

Keywords Bladder flap haematoma · Laparoscopy · Caesarean section · Ultrasonography · Obstetrical complication

Introduction

Caesarean section (CS) is the most frequently utilized intraperitoneal obstetric surgical event, and the two most common techniques used around the world are the Misgaw Ladach technique (or Stark CS) [1] and the traditional method [2].

The difference between these methods is in the closure of the peritoneum: the first one does not utilize peritoneal closure, and the second one closes the abdomen with suturing of the visceral and parietal peritoneum. The Stark method is believed to determine anatomical changes instead of the classic technique of Pfannenstiel-Kerr, in which the abdomen is closed with suturing of the visceral and parietal peritoneum [2].

The parietal non-sutured peritoneum, particularly, evokes abdominal wall anatomical modification in the Retzius or vesicouterine space, which normally can be the post-surgical fluid collection site, particularly after a CS.

In a CS, performed without visceral peritoneum suturing, the vesicouterine space communicates with the large peritoneal cavity [3]. If during a CS without use of the visceral and parietal peritoneum suturing technique some pathological fluid collections arise in this space, this decants its content into the large peritoneal cavity, and if the post-operative haemostasis is inadequate, a subfascial haematoma (SFH) can develop and, finally, haemoperitoneum [4].

Thus, an unusual complication of CS is the bladder flap haematoma (BFH). As a result of bleeding at the incision site, a haematoma forms between the bladder and lower uterine segment (LUS), so that a BFH is generally thought of as a blood collection in a potential space located between the urinary bladder and LUS (vesicouterine space) [5]. These collections can also extend over the bladder and uterus beneath the peritoneal reflection.

First case report

A 38-year-old female, second pregnancy, without risk factors, with a body mass index (BMD) of 24 and a mean blood pressure of 90 mmHg, underwent repeat caesarean delivery.

The visceral peritoneum was sutured at the end of CS, as in the traditional technique. The newborn's weight was 3,200 g with an Apgar score of 8 at the 1st min and 10 at the

A. Tinelli (✉) · R. Tinelli · F. G. Tinelli
Department of Obstetrics and Gynecology, Vito Fazzi Hospital,
Piazza Muratore,
73100 Lecce, Italy
e-mail: andtinelli@libero.it
Tel.: +39-34-75550039
Fax: +39-08-32661511

A. Malvasi
Department of Obstetrics and Gynecology,
Santa Maria Hospital,
Bari, Italy

C. Cavallotti
Department of Cardiovascular and Respiratory Sciences,
Section of Anatomy, University "La Sapienza",
Rome, Italy

5th min. On the 3rd post-operative day, the patient had lower abdominal pain and anaemia (haemoglobin of 6.2 mg/dl). Transabdominal ultrasonographic evaluation (TAUE) showed the presence of a BFH of 11×8×6 cm (Fig. 1).

In agreement with the patient, the post-operative follow-up was performed by serial TAUEs in 102 days to evaluate the BFH dimension and evolution; at the end of this period, the patient showed dysuria, persistent lower abdominal pain and fever (38.7°C).

So, in agreement with the infectivologist, we began antibiotic therapy with ceftriaxone (4 g/daily) plus tobramycin (160 mg/daily) for 10 days, but no important improvement was observed and the patient was submitted to laparoscopic treatment.

We performed the abdominal first access creating a pneumoperitoneum with a Verres needle, inserted into the umbilical zone, an optical first trocar introduction (EndoTIP, Karl Storz Endoscopy, Tuttlingen, Germany) and three additive trocars (two of 5 mm diameter in the classic lateral zone and one of 10 mm diameter in the suprapubic zone).

The pelvic-abdominal inspection showed a 10-cm right tumescence between the posterior bladder wall and anterior lower uterine body, as visualized by TAUE, and we proceeded in the following way.

By a transversal incision of 2 cm with bipolar forceps, we decollated the bladder wall from the BFH and performed some biopsies of the borders of the BFH surface, draining the purulent material with abscess characteristics (Fig. 2). Then, after exposure of the cavity surface of the BFH, we washed it with polyvinylpyrrolidone solution, diluted at 20% and sutured its border with some Vicryl 2-0 singular stitches, for a marsupialization.

At the end of laparoscopy we placed a catheter inside the pelvis for drainage; the total operative laparoscopic time was of 47 min, with minor blood loss (<20 ml) and no post-operative complications.

The woman was discharged after 48 h and the TAUE performed on the 2nd post-operative day showed an important reduction of the BFH; the final histological examination of the BFH and its borders showed purulent material with an abscess pseudo-capsule (Fig. 3).

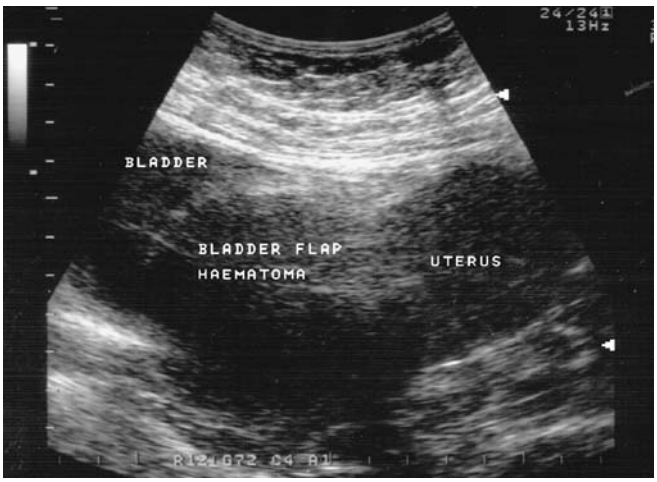

Fig. 1 Presence of a BFH of 11×8×6 cm

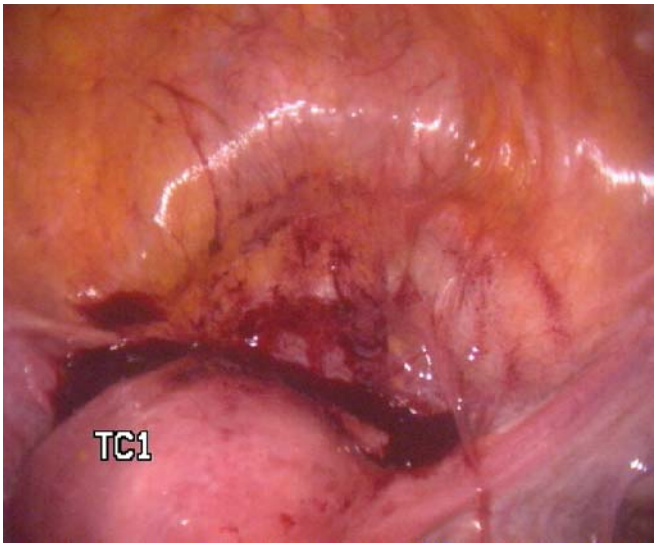

Fig. 2 Drainage of the purulent material with abscess characteristics

Second case report

A 31-year-old female, nullipara, without risk factors, with a BMD of 21 and a mean blood pressure of 82 mmHg, underwent caesarean delivery for cervical dystocia.

The visceral peritoneum was sutured at the end of CS, as in the traditional technique. The newborn's weight was of 3,450 g with an Apgar score of 9 at the 1st min and 10 at the 5th min. On the 4th post-operative day, the patient had lower abdominal pain and anaemia (haemoglobin of 8.3 mg/dl). TAUE showed the presence of a BFH of 9×7×5 cm (Fig. 4).

In agreement with the patient, the post-operative follow-up was performed, as in the first patient, by serial TAUEs in

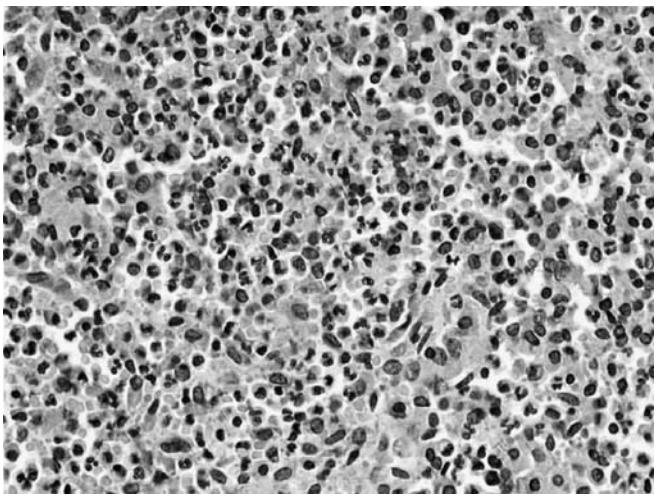

Fig. 3 The final histological examination of the BFH and its borders showed purulent material with an abscess pseudo-capsule

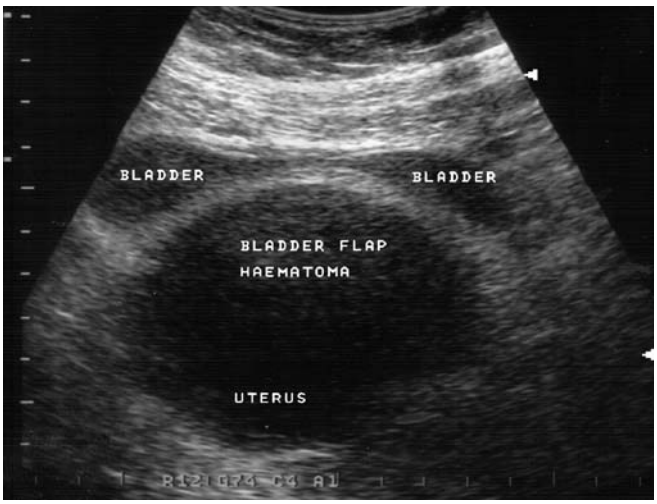

Fig. 4 The presence of a BFH of 9×7×5 cm

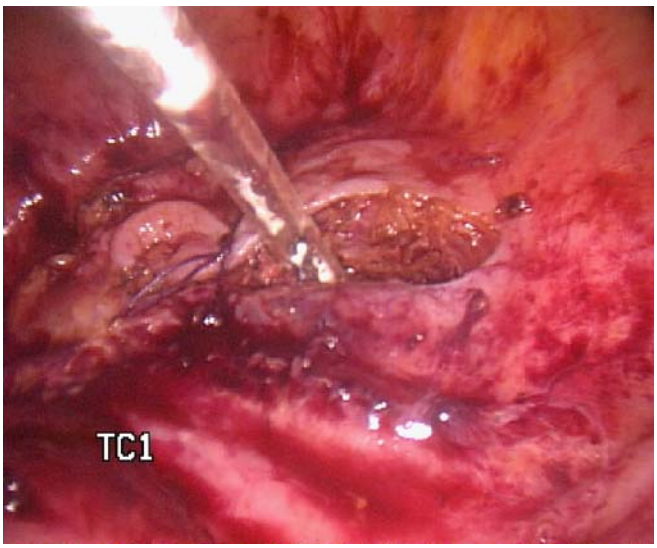

Fig. 5 The border of the BFH was sutured with some Vicryl 2-0 singular stitches, for a marsupialization

84 days and, at the end of this period, the patient was operated by laparoscopy for persistent lower abdominal pain and fever too (38.6°C).

As in the first patient, we performed the abdominal first access creating a pneumoperitoneum with a Verres needle, inserted into the umbilical zone, an optical first trocar introduction (ENDOPATH, Ethicon Endo-Surgery, Cincinnati, OH, USA) and three additive trocars (two of 5 mm diameter in the classic lateral zone and one of 10 mm diameter in the suprapubic zone).

The pelvic-abdominal inspection showed a 9-cm left tumescence between the posterior bladder wall and anterior lower uterine body, as visualized by TAUE, and we proceeded as in the first case: we decollated the bladder wall from the BFH, by a transversal incision of 2 cm with bipolar forceps. Then we performed some biopsies and drained the fluid material (with abscess characteristics), washing it with polyvinylpyrrolidone solution, diluted at 20%, and sutured its border with some Vicryl 2-0 singular stitches, for a marsupialization (Fig. 5).

At the end of laparoscopy we placed a catheter inside the pelvis for drainage; the total operative laparoscopic time was of 39 min, with minor blood loss (<20 ml) and no post-operative complications, as in the last patient.

The woman was discharged after 48 h and the post-operative TAUE showed an important reduction of the BFH; the final histological examination of the BFH and its borders showed purulent material with an abscess pseudo-capsule (Fig. 6).

Discussion

During a CS, if the haemostasis has not obtained after closure of the uterine incision, a haematoma may rise up between the bladder and the lower uterine segment (LUS); the flap haematoma is adjacent to the incision in the LUS, but covered by a fold of the incised, reflected and re-approximated peritoneum, during surgery.

Ultrasonography (US) can detect this complication easily and accurately and it can be used as non-invasive monitor and guide for therapy. The post-CS BFH is an unusual complication, its frequency is variable and so is its treatment.

Baker et al. reported 13 patients, of 1,458 CS, with a BFH diagnosed by US; 5 of these were treated by antibiotics, 1 had an explorative laparotomy, 1 confirmed haematoma was not drained but followed by US and 1 patient required an hysterectomy for myometritis and uterine wound dehiscence [6].

Burger et al. previously examined the uterine scar in 48 patients by a post-CS US, without clinical exam; they speculated that a mass interposed between the bladder and LUS, at the site of the incision, could be secondary to tissue reaction or oedema, blood or serous fluid or partial wound separation [7].



Fig. 6 The final histological examination of the BFH and its borders showed purulent material with an abscess pseudo-capsule

A study by Winsett et al. implied that the subfascial haematoma is an extension of the BFH [8]; Weiner et al. sustained that there was no US evidence of direct extension between the retrovesical BFH and the prevesical subfascial haematomas [9].

Woo et al. reported that of 14 patients who had CS with a subsequent fever, 13 women had a BFH showed by magnetic resonance (MR) [10]; Lev-Toaff assessed 31 patients with a post-CS fever and found 4 haematomas either with MR either by US, and 1 of these required a laparotomy [11].

Faustin et al. studied 100 post-CS women; in 29% of these echo-free areas were detected anterior to the uterine incision site, which corresponded to the described fluid collections that were more frequently found in patients with excessive blood loss during surgery [12]. Of these, patients with an echo-free area anterior to the uterine incision site that was 3.5 cm large or more had significant post-operative morbidity.

The differentiation between a haematoma and an infected haematoma or abscess can be difficult, but the presence of air inside it gives an evidence for the latter; the haemorrhage usually is confined by overlying peritoneum but it may spread laterally along the broad ligaments into the retroperitoneum.

Nagele et al. reported that closure of the visceral peritoneum may determine the formation of the BFH; in fact, leaving the visceral peritoneum open prevents the formation of subperitoneal "pockets" [13].

In more than seven cases, with continued blood loss or abscess formation, an explorative laparotomy is performed; in our experience non-closure of the visceral peritoneum during a CS is associated with a lower febrile and infective morbidity, in accordance with reports from a Cochrane review and other authors [14–17].

However, if a BFH forms, in our experience it is possible to treat and resolve this complication successfully by performing laparoscopic treatment in the way we describe.

Conclusion

Laparoscopy is an effective method for management of BFH and it expands the spectrum of surgical gynaecology. Since the scientific literature currently does not provide that much evidence, several other studies or case reports are needed to show the possibilities and the advantages of laparoscopy in BFH treatment.

References

1. Holmgren G, Sjoholm L, Stark M (1999) The Misgav Ladach method of cesarean section: method description. Acta Obstet Gynecol Scand 78:615–621
2. Xavier P, Ayres-De-Campos D, Reynolds A, Guimaraes M, Costa-Santos C, Patricio B (2005) The modified Misgav-Ladach versus the Pfannenstiel-Kerr technique for cesarean section: a randomized trial. Acta Obstet Gynecol Scand 84 (9):878–882
3. Stark M, Finkel AR (1994) Comparison between the Joel-Cohen and Pfannenstiel incisions in cesarean section. Eur J Obstet Gynecol Reprod Biol 53(2):121–122
4. Malvasi A, Martino V, Vittori G, Scollo P (2003) Subfascial hematoma: sonographic evaluation of post transverse laparotomies with and without closet parietal peritoneum. Ultrasound Obstet Gynecol 22 (Suppl 1):173
5. Hohlagschwandtner M, Ruecklinger E, Husslein P, Joura EA (2001) Is the formation of a bladder flap at cesarean necessary? A randomized trial. Obstet Gynecol 98(6):1089–1092
6. Baker ME, Bowie JD, Killam AP (1985) Sonography of post-cesarean-section bladder-flap haematoma. AJR Am J Roentgenol 144(4):757–759
7. Burger NF, Darazs B, Boegs EGM (1982) An echographic evaluation during the early puerperium of the uterine wound after caesarean section. J Clin Ultrasound 10(6):271–274
8. Winsett MZ, Fagan CJ, Bedi DC (1986) Sonographic demonstration of bladder-flap hematoma. J Ultrasound Med 5 (9):483–487
9. Wiener DM, Bowie JD, Baker ME, Kay HH (1987) Sonography of subfascial hematoma after cesarean delivery. AJR Am J Roentgenol 148(5):907–910
10. Woo GM, Twikler DM, Stettler RW, Erdman WA, Brown CE (1993) The pelvis after cesarean section and vaginal delivery: normal MR findings. AJR Am J Roentgenol 161(6):1249–1252
11. Lev-Toaff AS, Baka JJ, Toaff ME, Friedmann AC, Radecki PD, Caroline DF (1991) Diagnostic imaging in puerperal febrile morbidity. Obstet Gynecol 78(1):50–55
12. Faustin D, Minkoff H, Schaeffer R, Crombleholme W, Schwarz R (1985) Relationship of ultrasound findings after cesarean section to operative morbidity. Obstet Gynecol 66(2):195–198
13. Nagele F, Karas H, Spitzer D, Staudach A, Karasegh S, Beck A, Husselein P (1996) Closure or nonclosure of the visceral peritoneum at cesarean delivery. Am J Obstet Gynecol 174 (4):1366–1370
14. Bamigboye AA, Hofmeyr GJ (2003) Closure versus non-closure of the peritoneum at caesarean section. Cochrane Database Syst Rev 4:CD000163. Review
15. Gemer O, Shenhav S, Segal S, Harari D, Segal O, Zohev E (1999) Sonographically diagnosed pelvic hematomas and postcesarean febrile morbidity. Int J Gynaecol Obstet 65 (1):7–9
16. Koutsougeras G, Karamanidis D, Chimonis G, Gottas N, Polydorou A, Elmazis CH, Chatzidis B (2003) Evaluation during early puerperium of the low transverse incision after cesarean section through vaginal ultrasonography. Clin Exp Obstet Gynecol 30(4):245–247
17. Honig J (2002) Is the formation of a bladder flap at cesarean necessary? A randomized trial. Obstet Gynecol 99(4):677