

Hysteroscopic myomectomy in a submucous fibroid near from tubal ostia and 5 mm from the serosa: a case report from the Endoscopy Service of Ginendo-RJ

Ricardo Bassil Lasmar ·
Paulo Roberto Mussel Barrozo ·
Daniela Baltar da Rosa · Bernardo Portugal Lasmar ·
Waldir P. Modotte · Rogério Dias

Received: 31 May 2008 / Accepted: 25 June 2008 / Published online: 11 July 2008
© Springer-Verlag 2008

Abstract This is a case report of a 27-year-old white woman, nuliparous, single, who presented a heavy menstrual flow with clots, dysmenorrhoea and anaemia. Gynaecological examination of the uterus revealed anteverted position, mobility, no pain, slight enlargement and right displacement. Magnetic resonance imaging of the pelvis showed a 29-mm submucous fibroid with intramural component more than 50%, type 2, in the posterior wall, with a 5-mm distance from serosa. In office hysteroscopy, a 30-mm submucous fibroid with an intramural component with more than 50%, type 2, near around 5 mm from left tubal ostia, classified in STEP-W submucous fibroids classification as score 6, group II, was noted. GnRH analogue was indicated for 3 months before intervention

to treat anaemia. The patient was submitted to hysteroscopic myomectomy with direct mobilisation technique, with the fibroid completely removed without complications in a surgery which lasted for 52 min and 20 s.

Keywords Submucous fibroid · Hysteroscopy · Hysteroscopic myomectomy

Introduction

Hysteroscopic myomectomy has represented the standard minimally invasive surgical procedure for treating submucous fibroids since 1978 [1]. It eliminates the need for a laparotomy and is associated with lower morbidity than abdominal myomectomy [2]. Abnormal uterine bleeding and reproductive issues are the most common indications [3]. The benefits of the procedure are reflected by the improvement in menstrual pattern, fertility rate and overall patient satisfaction [2]. To achieve the full potentials of this technique, appropriate case selection and surgical expertise are essential [2]. It should be the preferred conservative surgical therapy for management of symptomatic intracavitary fibroids [4].

The choice of the technique mostly depends on fibroid intramural extension, as well as on personal experience and available equipment [4]. This evaluation is frequently only done with hysteroscopy and transvaginal ultrasound. Meanwhile, magnetic resonance imaging (MRI) gives more accurate information depending on penetration and the number of fibroids [5].

One of the factors associated with myomectomy complexity is fibroid penetration level; the European Society of Gynaecological Endoscopy (ESGE) classified them in three

R. B. Lasmar
Gynaecology Service of Pedro Ernesto Hospital,
Rio de Janeiro State University,
Rio de Janeiro, Brazil

R. B. Lasmar · P. R. M. Barrozo
School of Medicine,
Teresópolis, Rio de Janeiro, Brazil

P. R. M. Barrozo · D. B. da Rosa · B. P. Lasmar
Gynaecology Service of Ginendo,
Rio de Janeiro, Brazil

W. P. Modotte · R. Dias
Gynaecology, Obstetrics, and Mastology,
Botucatu School of Medicine—UNESP,
São Paulo, Brazil

R. B. Lasmar (✉)
Rua Voluntários da Pátria,
126 sala 602, Botafogo,
CEP 22270-010 Rio de Janeiro, Brazil
e-mail: ricardo@lasmar.com.br

levels [5]. Lasmar et al. [5] created a new classification, STEP-W classification, with five parameters to evaluate the surgery complexity [5].

All authors consider the distance between fibroid and serosa to be an important factor related to a large number of perforations and overload [3]. Literature has still not established a maximum safe limit for performing myomectomy; in our service, we consider 5 mm as the safe minimum distance [5].

Hysteroscopic myomectomy can be performed in one operation or in two or more operations, depending on submucous myoma classification and the importance of preserving uterine cavity for future pregnancy. Advincula and Song [7] reported that type 0 and 1 (ESGE) fibroids are considered safe for a one-time resection; however, type 2 carries a high risk of uterine perforation and intravasation complications [7].

Our case report demonstrated that applying a more precise classification allows better pre-operative evaluation. These parameters make it possible to plan and successfully perform a two-stage hysteroscopic myomectomy in one submucous fibroid, which is only 5 mm from the uterine serosa and 5 mm from the tubal ostia.

Case report

A 27-year-old, single, white, nuliparous woman came to our private service (Ginendo-RJ) with the diagnosis of uterine fibroid. She complained of heavy menstrual bleeding,

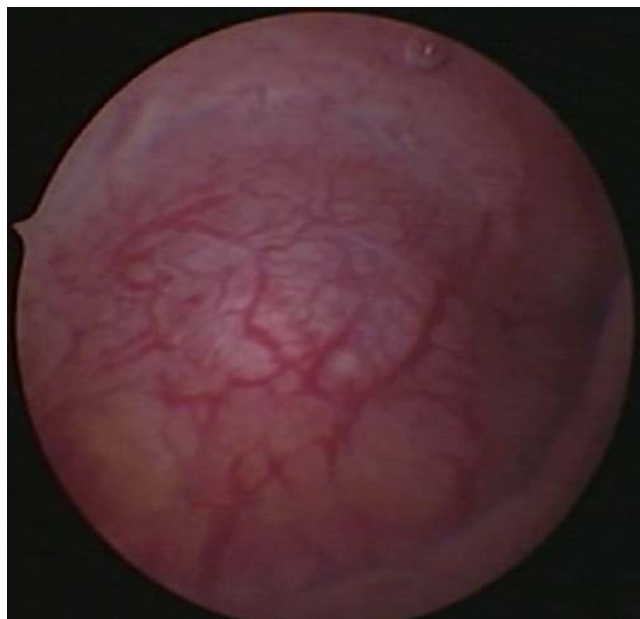

Fig. 1 Submucous fibroid near from tubal ostia

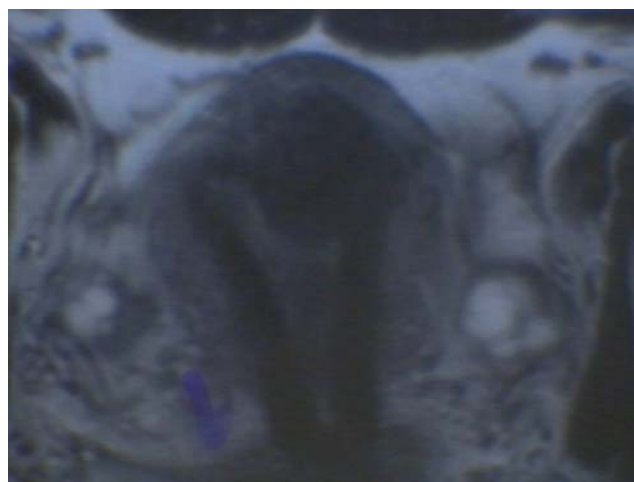


Fig. 2 MRI of the submucous fibroid 5 mm from serosa

passing clots, dysmenorrheal and fatigue. Menstrual cycles were 9/26. She wanted to become pregnant.

Gynaecological examination revealed a normal vulva, vagina and uterine cervix. The uterus was in an anteverted position, mobile, painless, slightly enlarged and turned to the right. Transvaginal ultrasound revealed AVF uterus, with heterogeneous myometrium, a 29-mm hypoechoic nodule extending from the fundus through to the endometrium. Adnexae were normal. MRI and office hysteroscopy were requested.

Hysteroscopy showed an ample and irregular uterine cavity with a 30-mm submucous fibroid with intramural component more than 50% of its volume, type 2 (ESGE). It occupied more than one third but less than two thirds of the

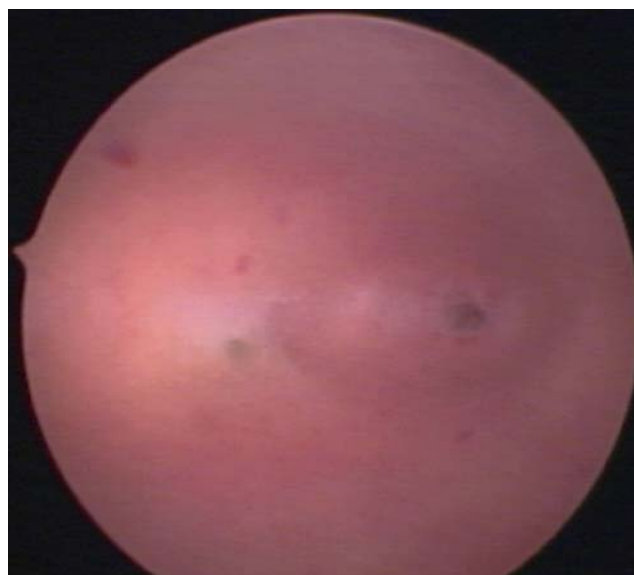


Fig. 3 Hysteroscopic view 2 months after surgery

posterior wall, in the upper third of the cavity, near 5 mm from the tubal ostia, score 6, group II, on STEP-W classification (Fig. 1).

MRI showed AVF uterus, with a submucous fibroid with more than 50% intramural component (type 2—ESGE), posterior wall, measuring 29×25×24 mm (9 cm³). The shortest distance between the serosa and fibroid was 5 mm (Fig. 2).

First, we prescribed three consecutive months of GnRH analogue for treatment of anaemia, and then hysteroscopic myomectomy was indicated. The patient was then advised of the possibility of surgical resection in two-time operations.

Hysteroscopic myomectomy was performed with complete nodule excision, using monopolar resectoscope, with direct mobilisation and slicing techniques, without incident. At the end of the procedure, negative fluid balance was 1,500 ml, and operation time was 52 min and 20 s. The patient was discharged the next morning.

In direct mobilisation techniques, the Collins electrode is used to dissect the endometrium around the fibroid until getting to it. In the next step, the direct mobilisation of the fibroid is started in all directions, extruding it into the cavity. The coagulation was done only in the bleeding vessels. When the fibroid is in the cavity, it is possible to remove it with grasping forceps (small fibroids) or to slice it in several pieces using the Collins electrode [8]. Two months later, a new office hysteroscopy was done, identifying uterine cavity with no fibroids or synechiae (Fig. 3).

Discussion

Hysteroscopic myomectomy is the ideal approach for submucous fibroids when the goal is to preserve the uterine matrix. The complexity of the surgery is directly related to the size and localisation of the myoma in the uterine cavity. To obtain the best surgical result, correct submucous fibroid classification is necessary to select the surgical instruments, the technique and the appropriate team for difficult cases [5, 9, 10]. In our experience, only one parameter is not sufficient to estimate the degree of complexity in a hysteroscopic myomectomy. The penetration of myoma in the myometrium is important but not enough to judge the difficulty of surgery. There are small myomas with deep level of penetration in the uterine wall, located in topography where it is easy to access with a resectoscope. Myomas with not-so-deep levels of penetration, located in thin uterine wall as cornual region, are very difficult to access with the resectoscope. They may represent more complex and difficult surgery, sometimes leading to ending the procedure without the complete withdrawal of the nodule.

In this case, we have a 30-mm fibroid, in the fundus, 5 mm close to the tubal ostia and 5 mm from the serosa. Even being an average-sized fibroid, its location was the major parameter in raising difficulties to perform the surgery.

The previous use of the GnRH analogue was indicated for the treatment of anaemia. In our service, we use the GnRH analogues only in patients with anemia or to provoke the diving of the fibroid into the cavity before the second hysteroscopic myomectomy.

There are some services using GnRH analogues to decrease the fibroid's size and vascularisation, intending to reduce the incidence of overload, but it increases the risk of uterine perforation [11]. We agree with Campo et al. that these advantages are not important for surgery [12]. Analysing this case report, we find support to expand the indication of hysteroscopic myomectomy in cases of submucous fibroids with intramural component, close from serosa. In these patients, we must have a more correct and complete submucous fibroid classification, using hysteroscopy and magnetic resonance imaging. Another determining factor will be the choice of the surgery technique. In this case, we decided to use the technique of direct mobilisation of the fibroid, allowing its gradual migration with less damage to the uterine cavity. This case report confirms that it is possible to overcome the limits of hysteroscopic myomectomy by carrying out correct submucous fibroid classification and precise planning of the surgical technique, always in the hands of experienced surgeons.

References

1. Neuwirth RS (1978) A new technique and additional experience with hysteroscopic resection of submucous fibroids. *Am J Obstet Gynecol* 131:91–94
2. Batra N, Khunda A, O'Donovan PJ (2004) Hysteroscopic myomectomy. *Obstet Gynecol Clin North Am* 31:669–685
3. Di Spiezio SA, Mazzon I, Bramante S, Bettocchi S, Bifulco G, Guida M, Nappi C (2008) Hysteroscopic myomectomy: a comprehensive review of surgical techniques. *Hum Reprod Updat* 14:101–119
4. Lefebvre G, Vilos G, Allaire C et al (2003) The management of uterine leiomyomas. *J Obstet Gynaecol Can* 25:396–418
5. Lasmar RB, Barrozo PRM, Dias R, Oliveira MA (2005) Submucous myomas: a presurgical classification to evaluate the viability of hysteroscopic surgical treatment. *J Minim Invasive Gynecol* 12(4):308–11
6. Wamsteker K, Emanuel MH, deKruif JH (1993) Transcervical hysteroscopic resection of submucous fibroids for abnormal uterine bleeding: results regarding the degree of intramural extension. *Obstet Gynecol* 82:736–740
7. Advincula AP, Song A (2004) Endoscopic management of leiomyomata. *Semin Reprod Med* 22(2):149–55
8. Lasmar R, Barrozo P (2002) Histeroscopia: uma abordagem prática. *Rio de Janeiro Medsi* 1:121–142

9. Murakami T, Tamura M, Ozawa Y, Suzuki H, terada Y, Okamura K (2005) Safe techniques in surgery for hysteroscopic myomectomy. *J Obstet Gynaecol Res* 31(3):216–223
10. Lasmar RB, Barrozo PRM, Rosa DB, Dias R (2007) Hysteroscopic myomectomy in a submucous fibroid 3 mm from the serosa: a case report from the endoscopy service of Ginendo-RJ. *Ginecol Surg* 4:149–152
11. Gutmann JN, Corson SL (2005) GnRH agonist therapy before myomectomy or hysterectomy. *J Minim Invasive Gynecol* 12:529–537
12. Campo S, Campo V, Gambadauro P (2005) Short-term results of resectoscopic myomectomy with and without GnRH analogs in premenopausal women. *Acta Obstet Gynecol Scand* 84(8):756–760