

Laparoscopic removal of large submucous myomas

Rakesh Sinha · Meenakshi Sundaram ·
Chaitali Mahajan · Shweta Raje · Pratima Kadam ·
Gayatri Rao · Rinkita Sinha

Received: 2 January 2011 / Accepted: 9 January 2011 / Published online: 28 January 2011
© Springer-Verlag 2011

Abstract The aim of this study was to analyze the feasibility and technique of removing large submucous myomas laparoscopically. This technique decreases the complications of removing the submucous myoma hysteroscopically. The design was based on a retrospective review (Canadian Task Force Classification II-1) in a dedicated high volume gynecological laparoscopy centre. The subjects were twenty-two women who underwent laparoscopic removal of submucous myomas at our center. Laparoscopic removal of submucous myoma was done in all patients in whom the size of the myoma was more than 5 cm. The results revealed the following: (1) median clinical size of the uterus was 12 weeks (6, 18); (2) median size of the myoma was 7 cm (5, 10); (3) median weight of the specimen was 200 g (60, 460); (4) median total duration of surgery was 75 min (40, 120); (5) median total blood loss was 50 ml (10, 500); and the total morcellation time was 15 min (5, 45). Laparoscopic myomectomy for large submucous myomas is a technically feasible procedure. It can be performed by experienced surgeons irrespective of the size or depth of the myoma. It prevents the complications of hysteroscopic removal of the myoma.

Keywords Myomas · Myomectomy · Submucous myomas · Laparoscopic myomectomy · Hysteroscopic myomectomy

R. Sinha · M. Sundaram · C. Mahajan · S. Raje · P. Kadam ·
G. Rao · R. Sinha
Bombay Endoscopy Academy and Centre for Minimally Invasive
Surgery (BEAMS Hospital),
Mumbai, India

M. Sundaram (✉)
674, 16th Cross Road, Behind Khar Gymkhana,
Khar Pali, Khar (W),
Mumbai 400 052, India
e-mail: drmeena25@yahoo.com

Introduction

Uterine leiomyomas are one of the most common benign smooth muscle tumors in women, with a prevalence of 20–40% in women over the age of 35 years [1]. Submucous myomas are those that most frequently cause menorrhagia and infertility [2]. Hysteroscopic myomectomy is considered the first-line conservative surgical therapy for the management of symptomatic submucous fibroids [3]. Most studies have suggested beneficial effects in treating both menstrual abnormalities and infertility with this procedure. The few studies that have reported on long-term outcomes for fibroid-related menstrual abnormalities indicate that hysteroscopic myomectomy is associated with a 10–35% risk of surgical re-intervention, including repeat myomectomy, open myomectomy or hysterectomy [3]. Uterine bleeding, perforation and fluid overload are major complications which can occur during hysteroscopic myomectomy if not performed by an experienced surgeon. Prolonged surgery can cause fluid overload leading to electrolyte imbalances and its subsequent complications [4]. This can occur especially during hysteroscopic resection of large submucous myomas. To avoid the complications of hysteroscopy, laparoscopic removal of large submucous myomas can be done. In our centre, if the size of the submucous myoma is more than 5 cm on ultrasonography, we prefer to remove them by laparoscopic myomectomy.

Materials and methods

Twenty-two women who had submucous myomas more than 5 cm underwent laparoscopic myomectomy. The mean age was 34 years. Eleven patients were nulliparous, six women had previous normal delivery and the other five had

previous caesarean section. The indication for myomectomy was menorrhagia in all women, two complained of fibroid uterus and one had lump in the abdomen. The clinical size of the uterus varied from 6 weeks to a maximum of 18 weeks. The average maximum diameter of the myoma measured by ultrasonography was 7.5 cm. All patients underwent pelvic ultrasound examination and basic blood investigations. Patients were kept on a liquid diet 2 days before the procedure and a laxative was given 12 h before the surgery to empty the bowel. Antibiotic prophylaxis was given to all patients included in the study. Subcutaneous low-dose heparin and a sequential compression device were also given to all patients for prophylaxis against possible thromboembolic episodes.

Operative procedure

The surgeries are performed under general anesthesia with the patient in modified lithotomy position. A diagnostic hysteroscopy is done in all cases. The submucous myomas are visualised (Figs. 1, 2 and 3). The size and extent of the myoma inside the cavity were assessed. The angle of the myoma with respect to the uterine cavity is assessed. If the myoma has more than 50% intramural extension and the size of the myoma is more than 5 cm, then we proceed to do a laparoscopic myomectomy.

Veress needle is inserted at the Palmer's point. The Palmer's point [5] (a point 3 cm below the left costal margin in the midclavicular line) is a safe zone in all patients other than those with splenomegaly.

After insufflation with carbon dioxide, a 5-mm trocar is inserted blindly in the left upper quadrant above the level of the umbilicus almost close to the Palmer's point. A 10-mm

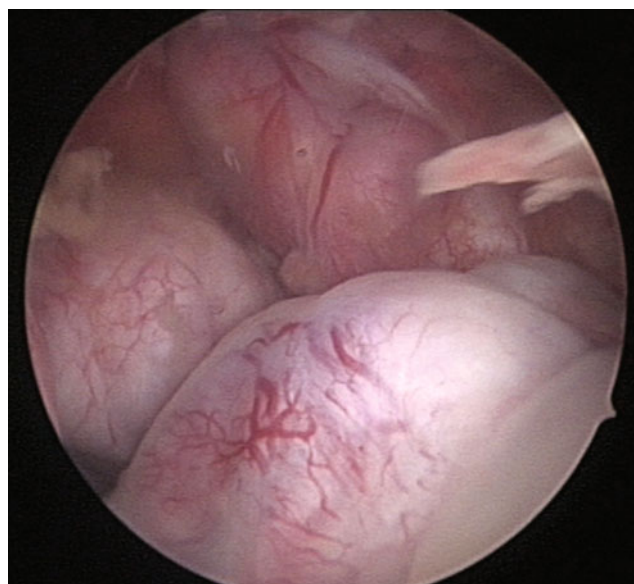


Fig. 2 Multiple submucous myomas on hysteroscopy

optical port is inserted supraumbilically. This port is inserted under vision through the left lateral port. We used three 5-mm accessory ports; the port placed initially in the left lateral upper quadrant is used as the first accessory port. The second port is placed under vision in the right lateral upper quadrant and the third port is placed in the left lateral lower quadrant.

At laparoscopy, the uterus is usually uniformly enlarged or shows evidence of fibroid projecting from one of the walls. The adnexa are visualised. A horizontal incision is made on the fundus of the uterus or on the most prominent part of the fibroid (Fig. 4). As the incision is widened and deepened, the submucous fibroid can be visualised. The 5-mm myoma spiral is used to enucleate the myoma. By

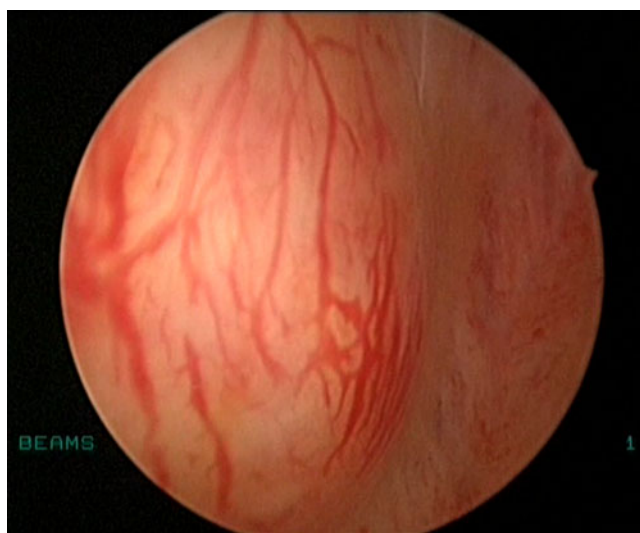


Fig. 1 Submucous myoma on hysteroscopy

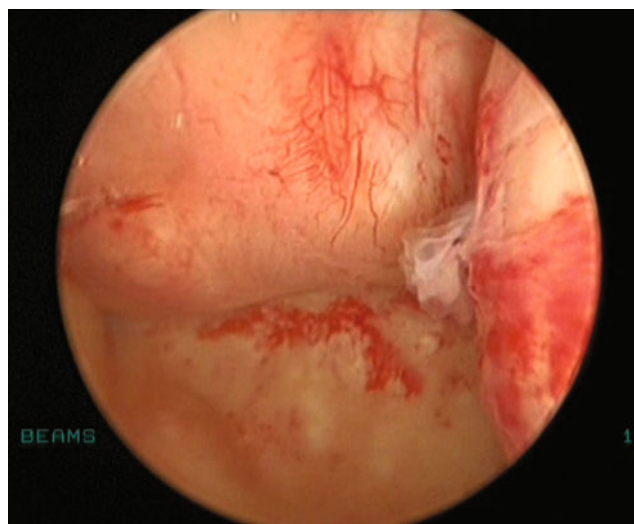


Fig. 3 Large submucous myomas

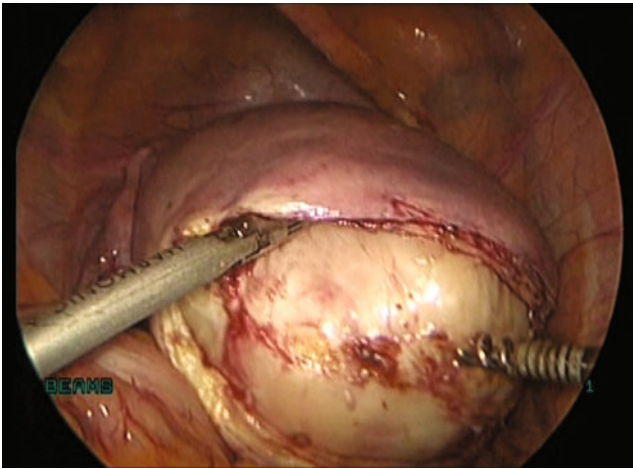


Fig. 4 Horizontal incision on the myoma laparoscopically

gentle traction and countertraction, the myoma is enucleated completely (Fig. 5). Precaution should be taken while enucleating the myoma to prevent damage to the underlying endometrium (Fig. 6). The endometrium is separated from the myoma carefully and repositioned in the cavity. Even if the endometrial cavity is opened incidentally (Fig. 7), it is repositioned and the myoma bed is sutured. We do not suture the endometrial lining.

The myometrial bed is sutured in two layers: first, mattress to obliterate the dead space and second, figure of eight interrupted sutures (Fig. 8). Adhesion barrier is placed on the suture line. In some patients where the myoma is very large, we also ligate the uterine vessels bilaterally before myomectomy. In such cases, the uterovesical fold of peritoneum is opened initially and the bladder is pushed down. The uterine vessels are identified bilaterally and ligated with no: 1-0 delayed absorbable sutures. Once the uterines are ligated, the myoma gets devascularised and the blood loss during the procedure is considerably reduced [6]. The enucleated

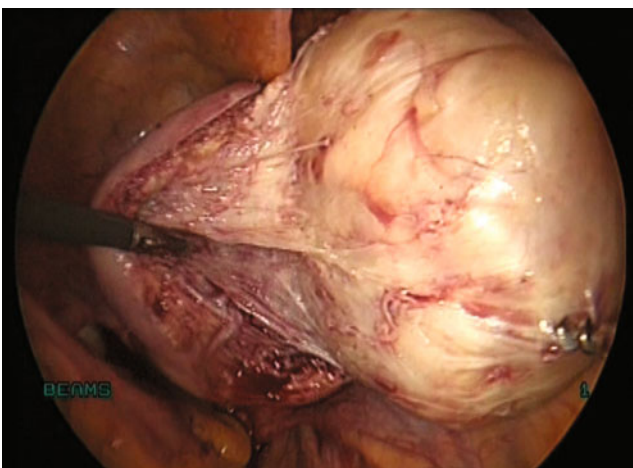


Fig. 5 Enucleation of myoma

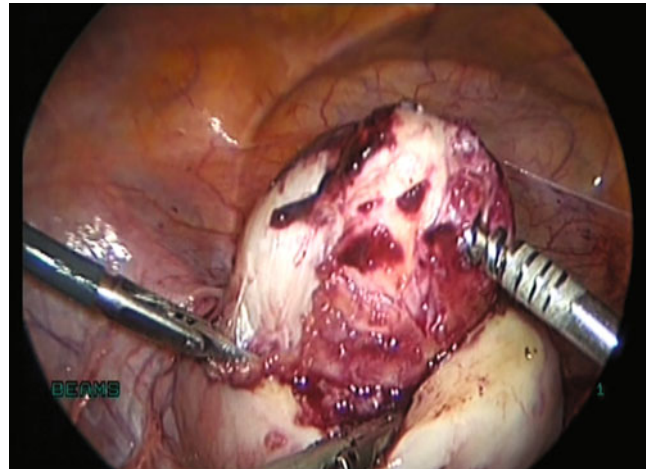


Fig. 6 Enucleation of the submucous myoma preserving the endometrium

myoma is then retrieved by an electromechanical morcellator through a 12-mm port (Figs. 9 and 10).

The total blood loss is calculated. The time taken for surgery from the insertion of Veress to the last skin suture is noted. Skin is sutured with 3-0 delayed absorbable subcuticular sutures. The specimen is sent for histopathological examination. The urinary catheter is removed after 12 h. Patients are started on liquid diet 6 h after the surgery.

Data analysis

Analysis was done using SPSS for Windows, Version 14.0 (SPSS Inc., Chicago, IL). Results are expressed as median (minimum, maximum). All procedures were performed laparoscopically. The following data were obtained: (1) median clinical size of the uterus was 12 weeks (6, 18); (2) the median size of the myoma was 7 cm (5, 10); (3) the

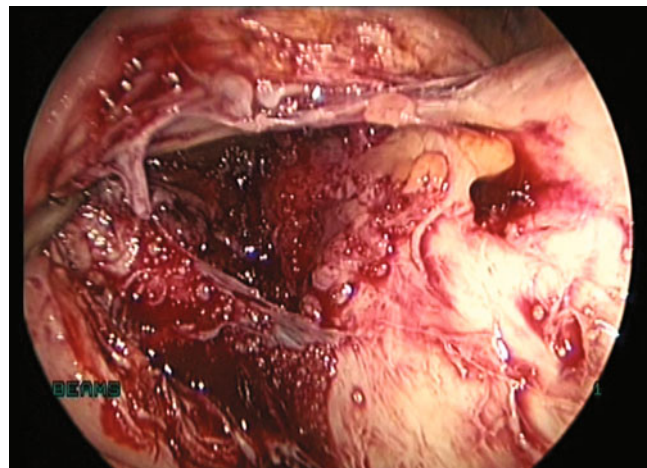


Fig. 7 Opened endometrial cavity during myoma enucleation

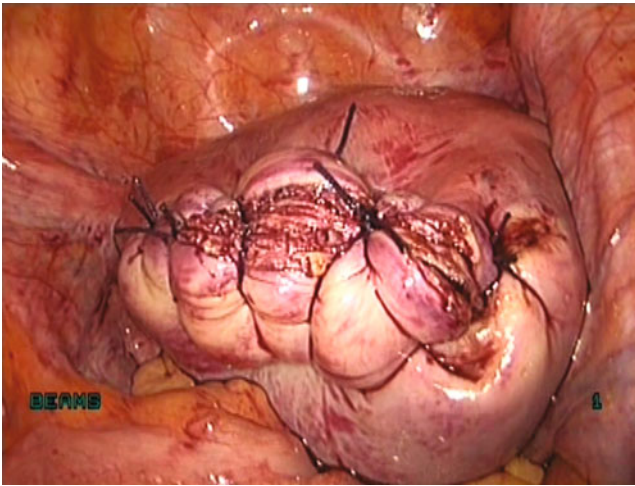


Fig. 8 Sutured myoma bed

median weight of the specimen was 200 g (60, 460); (4) the median total duration of surgery was 75 min (40, 120); (5) the median total blood loss was 50 ml (10, 500); and (6) the total morcellation time was 15 min (5, 45). Histopathological examination showed leiomyoma in all patients.

The data reveal that there is no complication associated with laparoscopic resection in any of the patients. Even large submucous myomas can be removed with minimal blood loss.

Discussion

Hysteroscopic myomectomy is a therapeutic option for the treatment of submucous fibroids. However, transcervical resection of fibroids with deep intramural extension is performed only in selected patients [7]. A major concern is that complete hysteroscopic resection might result in uterine perforation or fluid overload [4]. As hysteroscopic myomectomy is at times a highly complex procedure, its

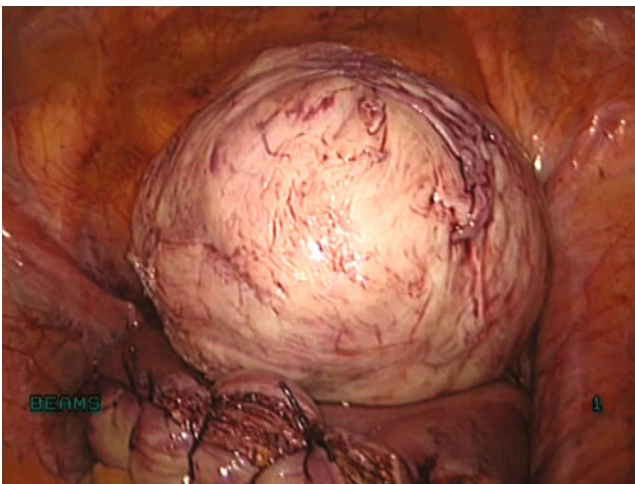


Fig. 9 Submucous myoma removed laparoscopically

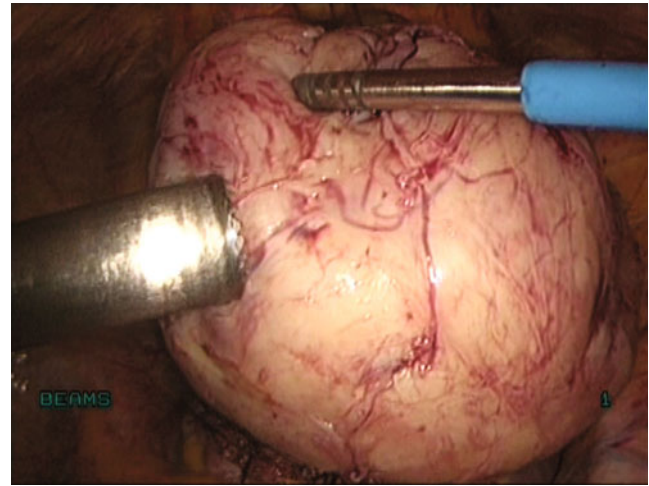


Fig. 10 Myoma retrieved by morcellation

real feasibility must be evaluated correctly preoperatively in order to minimize the morbidity and mortality that can occur during the procedure.

Conventionally, hysteroscopic myomectomy is not advisable if the myoma is larger than 5 or 6 cm, if more than 50% of the endometrial surface is affected by myoma size or number, or if the size of the uterine cavity has been limited to that of 16 weeks of gestation [8]. Some authors have described two stage hysteroscopic myomectomy for removal of large submucous fibroids [9]. Myomas with the greatest diameter within the uterine wall have been associated with increased operating time and potential side effects, such as heavy hemorrhage, difficulty to control uterine perforation and water intoxication, and often require a second-stage operation to remove the myoma when the remaining portion of the submucous fibroid has been pushed into the uterine cavity by continuous myometrial contraction [10].

In order to avert the complications of hysteroscopic myomectomy and avoid an incomplete excision, we perform laparoscopic myomectomy for patients with large submucous fibroids more than 5 cm. Laparoscopic approach to remove these fibroids prevented the complications of hysteroscopy, and intraoperative blood loss during laparoscopic removal was minimised by uterine artery ligation.

A study by Wang et al. [11] concluded that, in the presence of a submucous fibroid larger than 4 cm and with an intramural extension greater than 50%, laparoscopic rather than hysteroscopic myomectomy can be performed for the sake of safety and, if needed, for the concomitant removal of fibroids of a nonsubmucous type. However, this particular approach should be performed only by surgeons skilled in laparoscopic suturing.

The concerns of laparoscopic removal of submucous fibroids are mainly: opening the endometrial cavity, healing of suture line, and possibility of subsequent pregnancy and risk of uterine rupture during pregnancy. The events leading to

dehiscence are thought to include suboptimal suturing of the uterine incision and/or impaired wound healing from extensive use of coagulation or any tissue-destroying modality [12]. Studies have shown that if the uterine myometrium is well approximated with sutures, there is no increased risk of uterine rupture even if the endometrial cavity was opened.

Seracchioli et al. [13] described laparoscopic myomectomy for deeply penetrating fibroids as a safer option. They described that the risk factors for uterine rupture in subsequent pregnancy include failure to adequately approximate the myometrium, using the wrong suture, electrically caused necrosis and surgeon's inexperience. They avoided the extensive use of thermal energy for haemostasis because it might lead to poor vascularisation and tissue necrosis with an increased risk of uterine rupture and fistula formation.

Conclusion

We believe that for the experienced laparoscopic surgeon skilled in endoscopic suturing, achieving good uterine closure is possible even in difficult conditions. Hence, laparoscopic myomectomy is a better treatment option for patients with submucous fibroids more than 5 cm in size and if the intrauterine extension is more than 50%. The major advantage is that the procedure prevents the risk of hysteroscopy complications.

Declaration of interest The authors report no conflicts of interest. The authors alone are responsible for the content and writing of the paper.

References

1. Solomon LA, MD VL, Schimp DO (2005) Clinical update of smooth muscle tumors of the uterus. *J Minim Invasive Gynecol* 12:401–408
2. Narayan R, Goswamy RK (1994) Treatment of submucous fibroids and outcome of assisted conception. *J Am Assoc Gynecol Laparosc* 1(4 Pt 1):307–311
3. Indman PD (2006) Hysteroscopic treatment of submucous myomas. *Clin Obstet Gynecol* 49(4):811–820
4. Sinha M, Hegde A, Sinha R (2007) Parotid area sign: a clinical test for the diagnosis of fluid overload in hysteroscopic surgery. *J Minim Invasive Gynecol* 14:161–168
5. Sinha R, Hegde A (2005) Safe entry techniques during laparoscopy. *J Minim Invasive Gynecol* 12:463–465
6. Sinha R, Sundaram M, Nikam YA et al (2008) Total laparoscopic hysterectomy with earlier uterine artery ligation. *J Minim Invasive Gynecology* 15(3):355–359
7. Wamsteker K, Emanuel MH, de Kruijff JH (1993) Transcervical hysteroscopic resection of submucous fibroids for abnormal uterine bleeding: results regarding the degree of intramural extension. *Obstet Gynecol* 82:736–740
8. Neuwirth RS (1995) Hysteroscopic submucous myomectomy. *Obstet Gynecol Clin North Am* 22:541–558
9. Donnez J, Polet R, Smets M, Bassil S, Nisolle M (1995) Hysteroscopic myomectomy. *Curr Opin Obstet Gynecol* 7:311–316
10. Crosignani PG, Vercellini P, Meschia M, Oldani S, Bramante T (1996) GnRH agonists before surgery for uterine leiomyomas: a review. *J Reprod Med* 41:415–421
11. Wang CJ, Soong YK, Lee CL (2007) Laparoscopic myomectomy for large intramural and submucous fibroids. *Int J Gynecol Obstet* 97:206–207
12. Gary N, Frishman MD, Marcus W, Jurema MD (2005) Myomas and myomectomy. *J Minim Invasive Gynecol* 12:443–456
13. Seracchioli R, Colombo FM, Bagnoli A et al (2003) Laparoscopic myomectomy for fibroids penetrating the uterine cavity: is it a safe procedure? *Br J Obstet Gynaecol* 110:236–240